

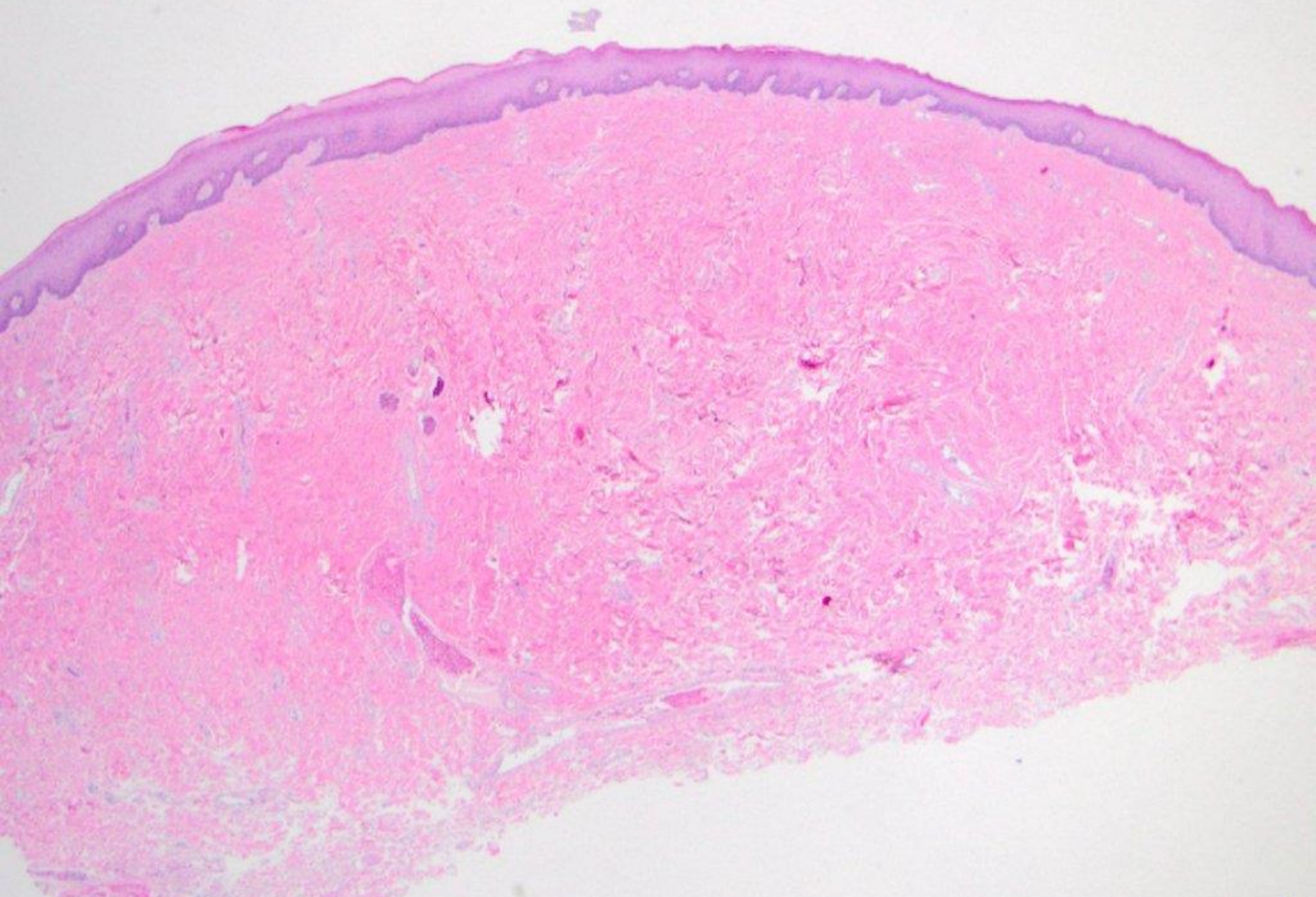
Oral Histopathology

Series 33

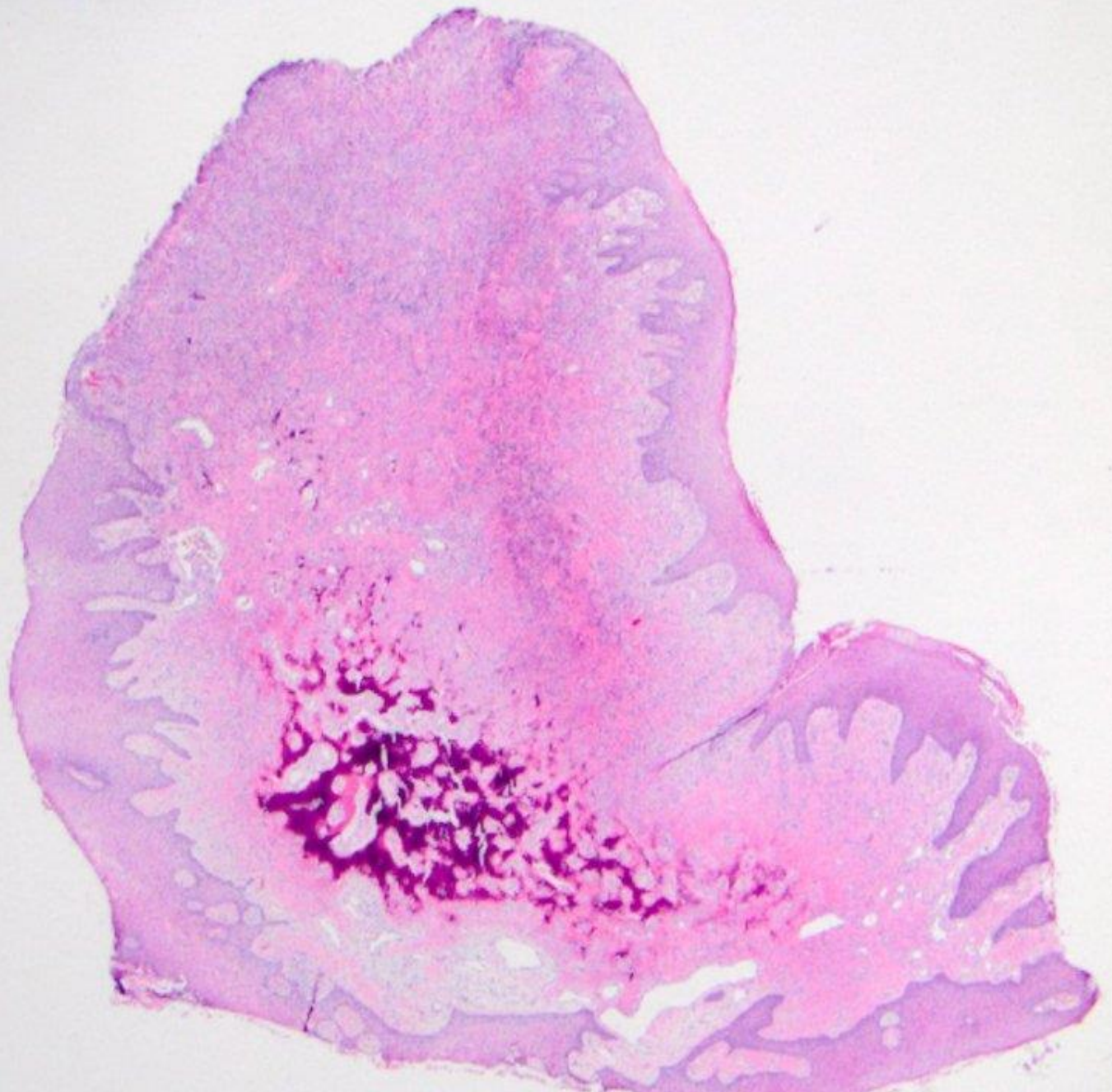
DAVID E. KLINGMAN, DMD

Diplomate, American Board of Oral and Maxillofacial Pathology

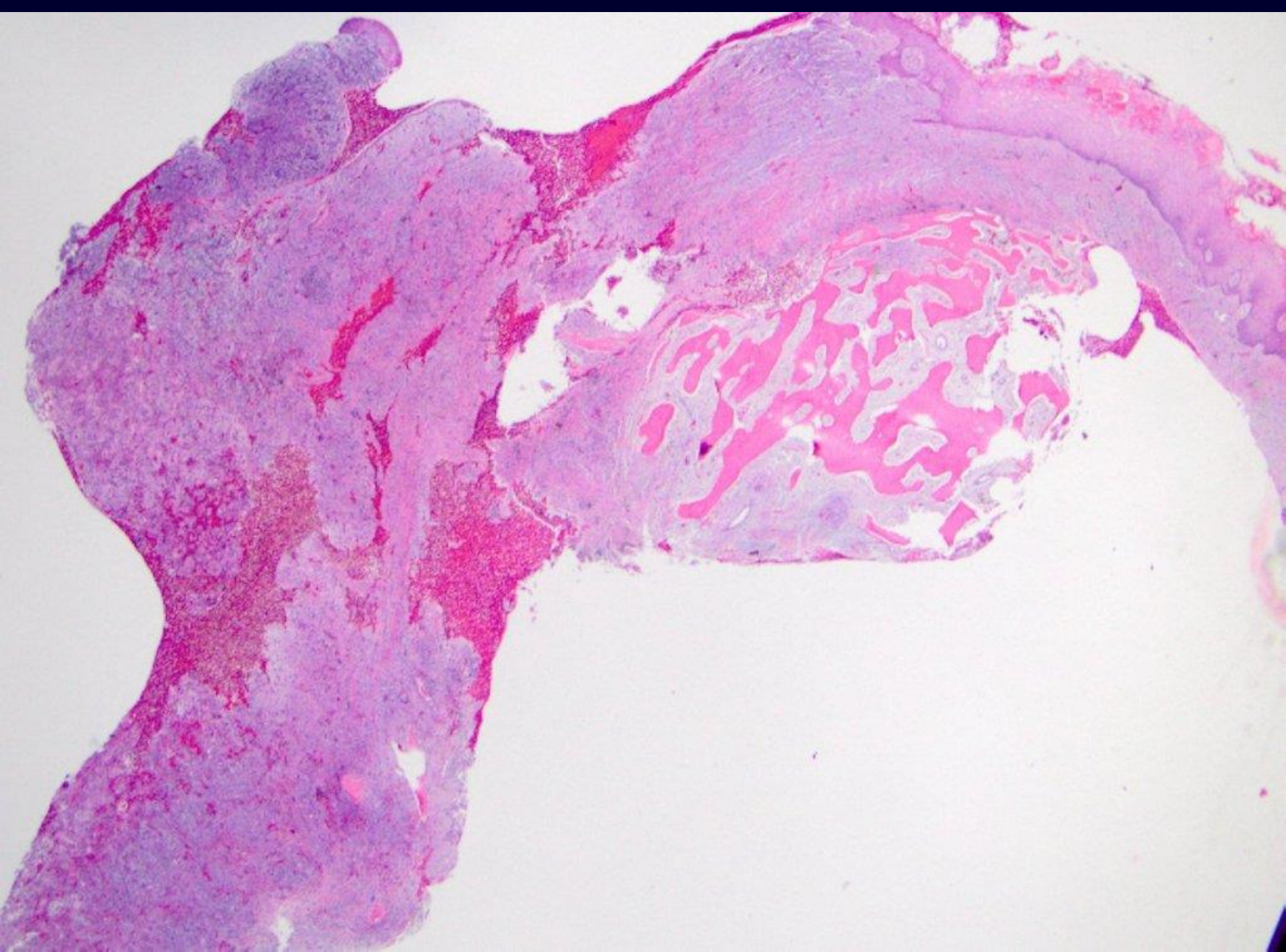
Diplomate, American Board of General Dentistry

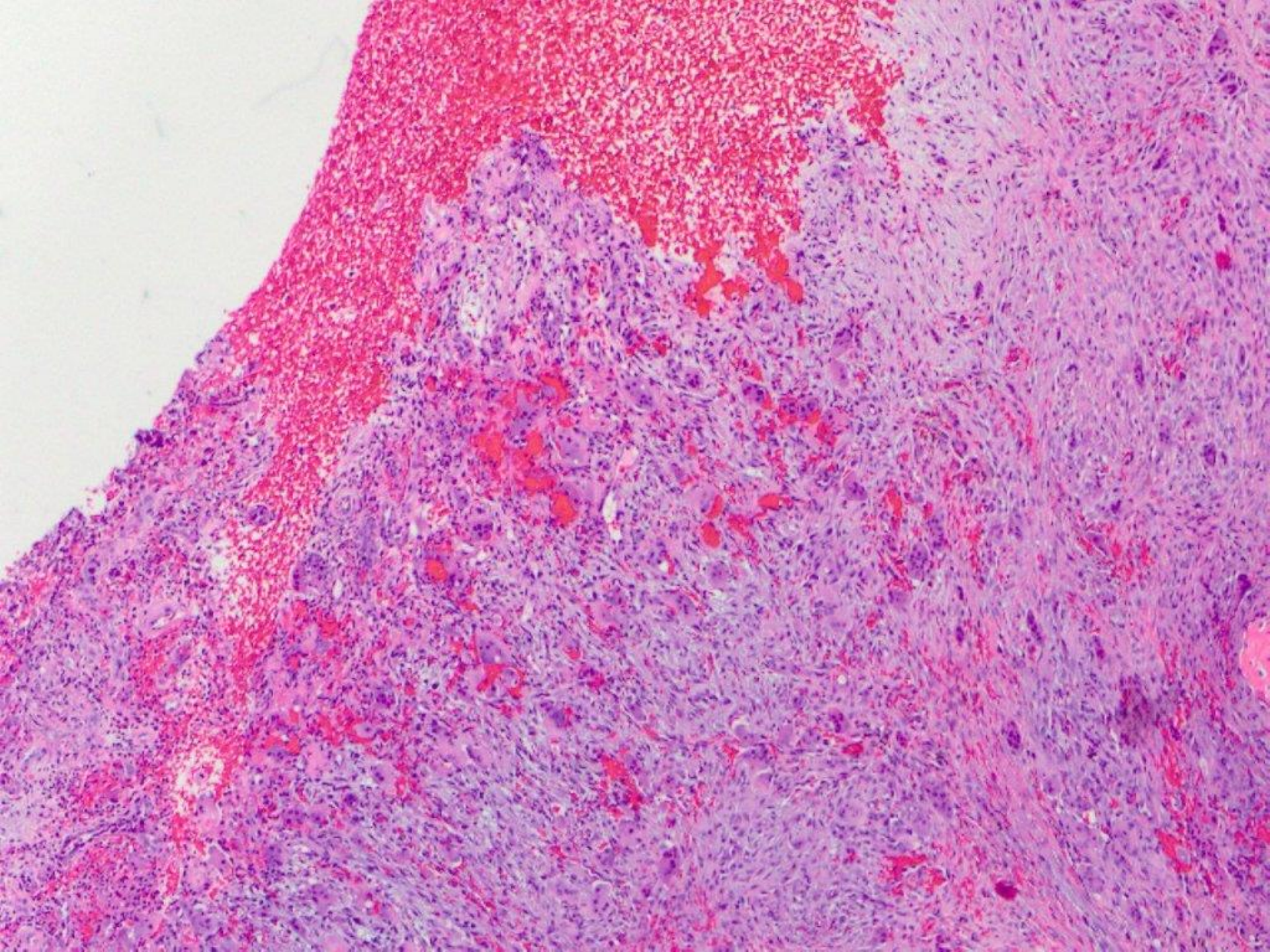


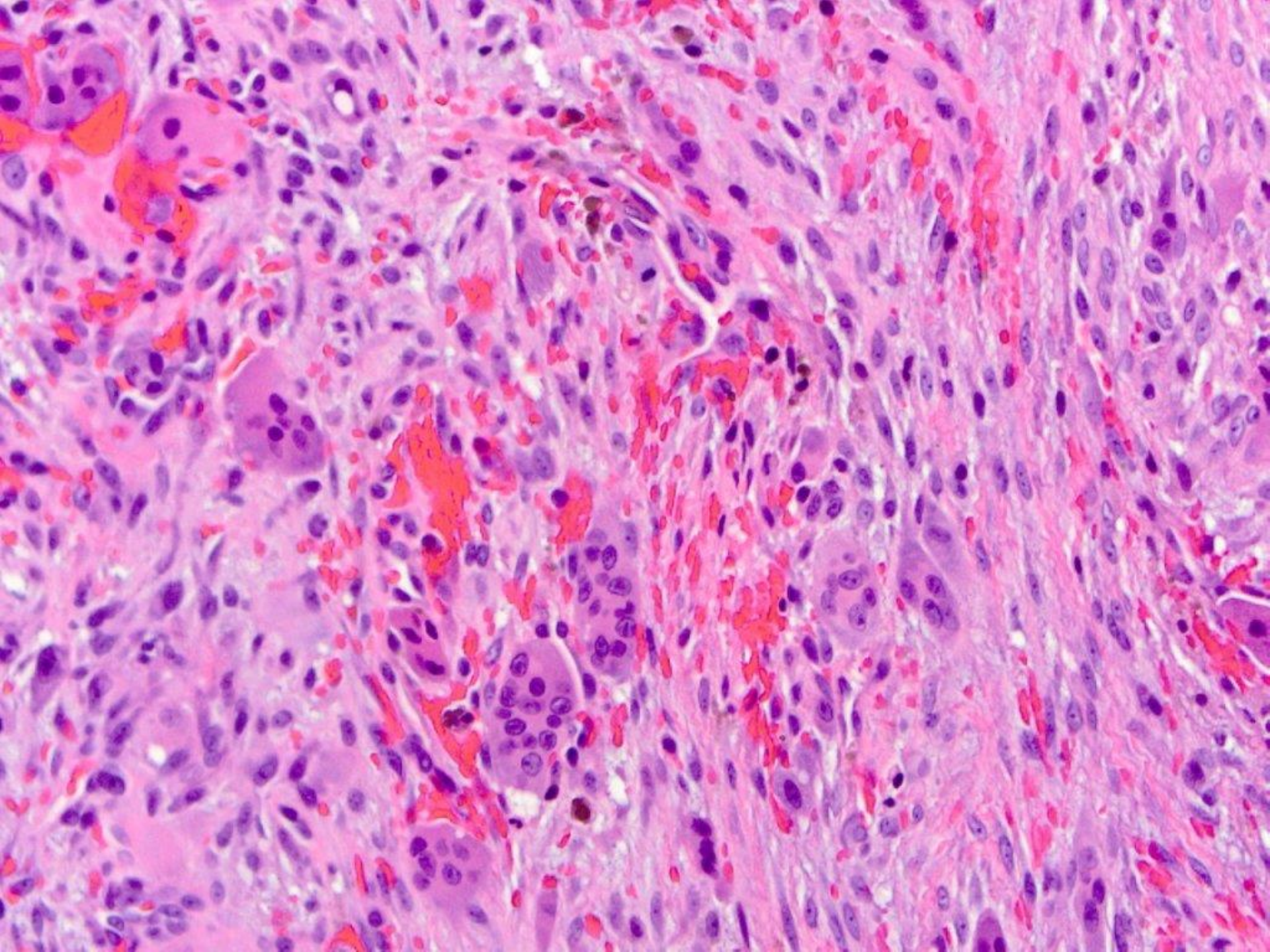
fibroma

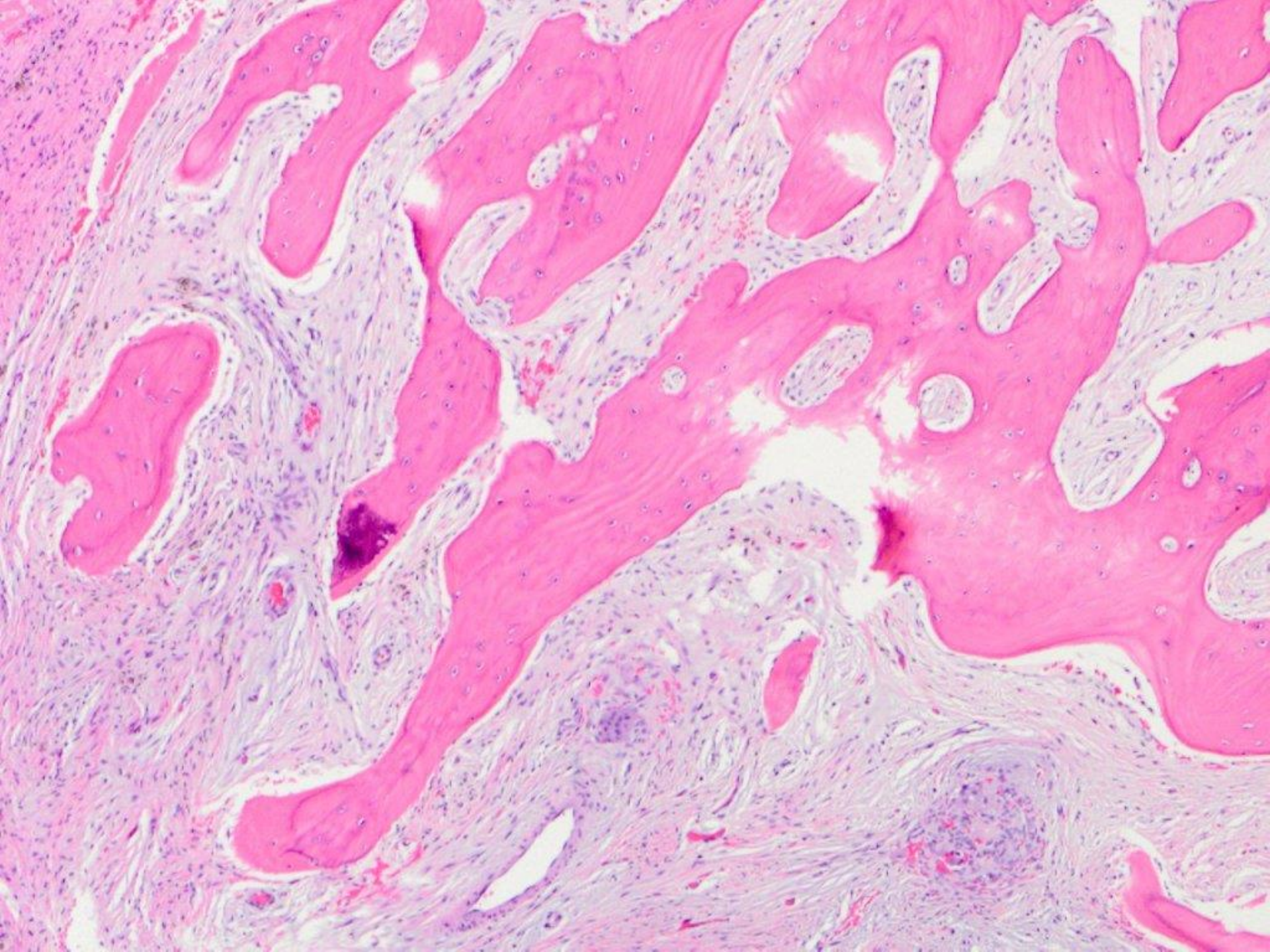


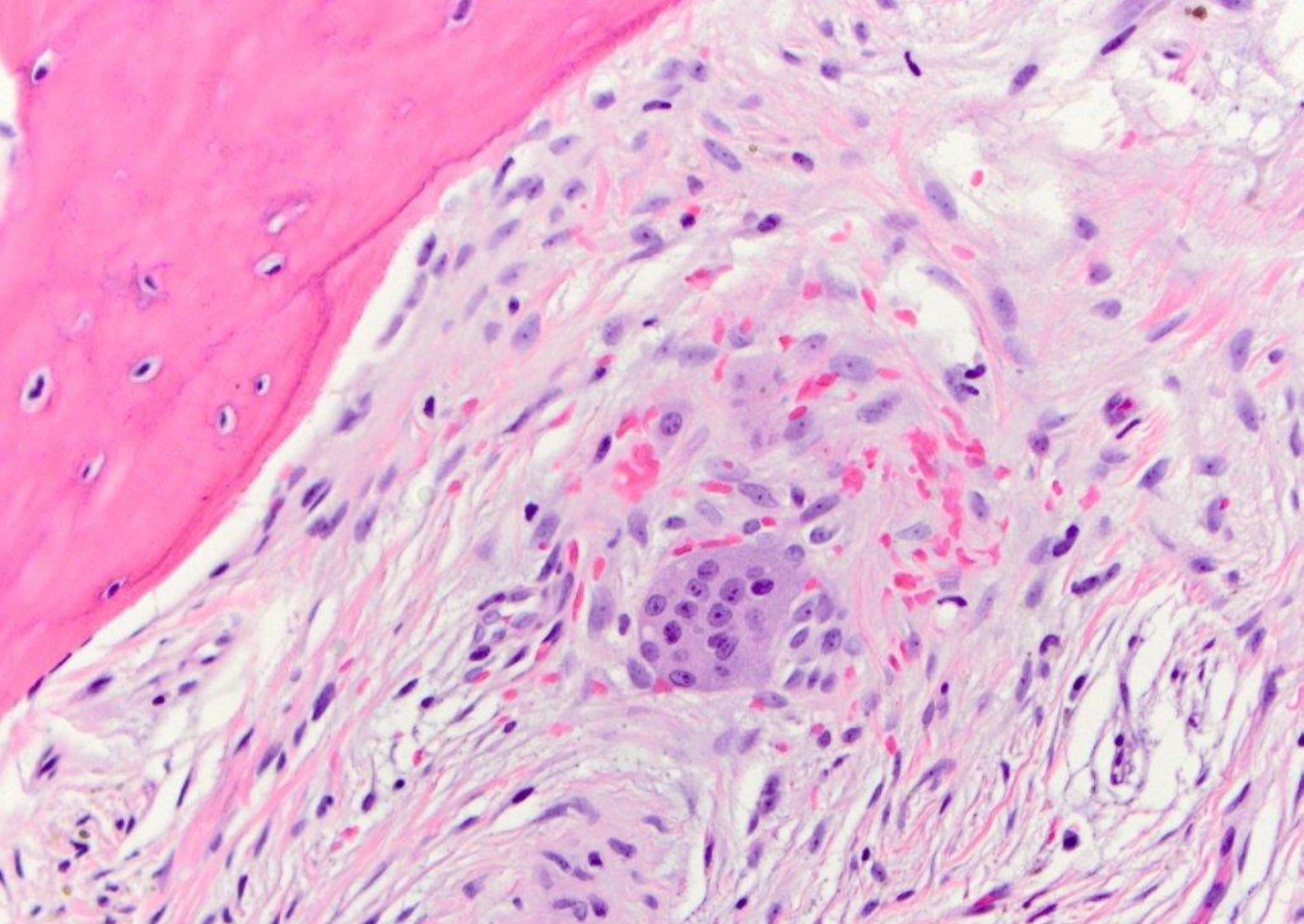
Ulcerated peripheral ossifying fibroma



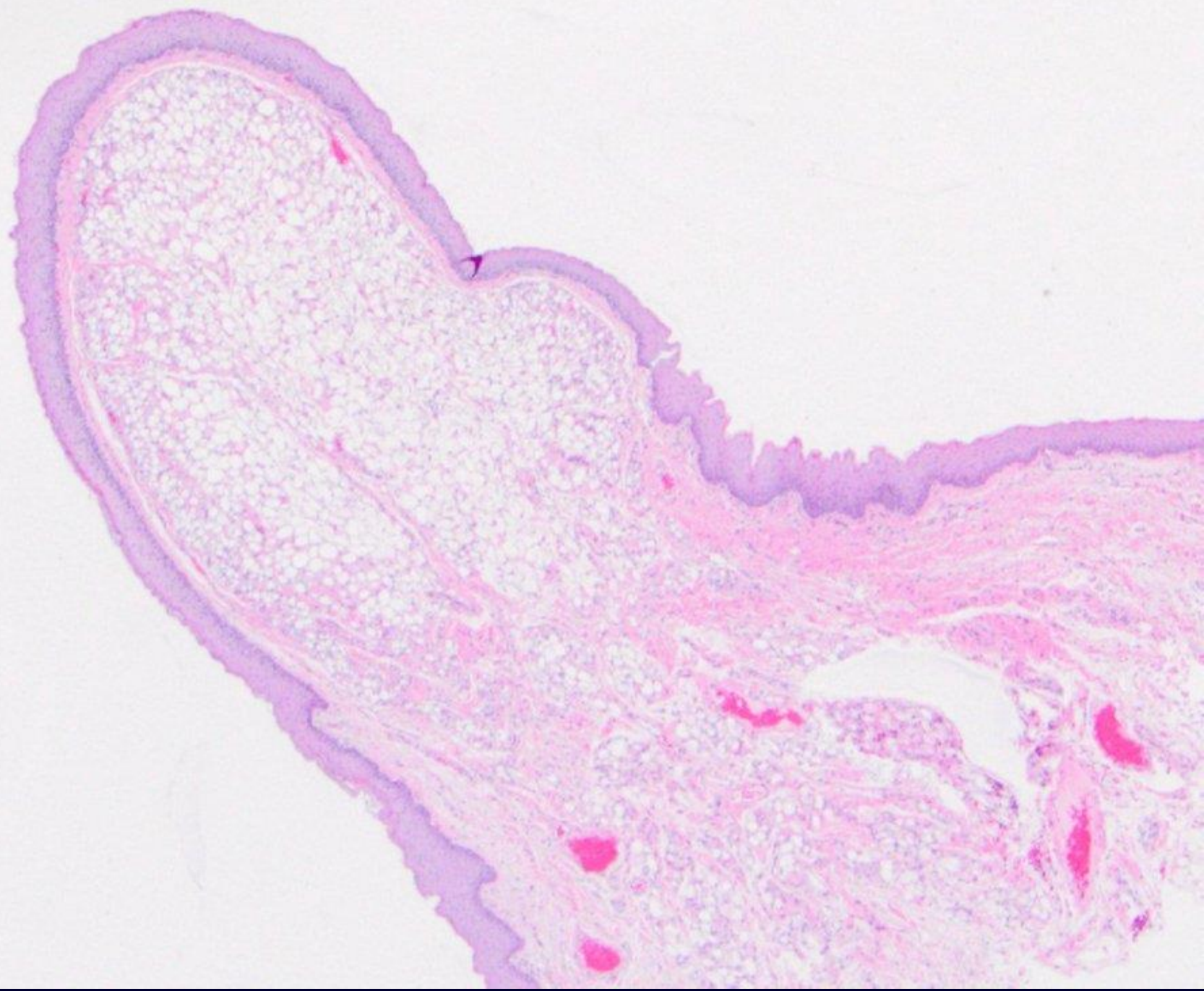


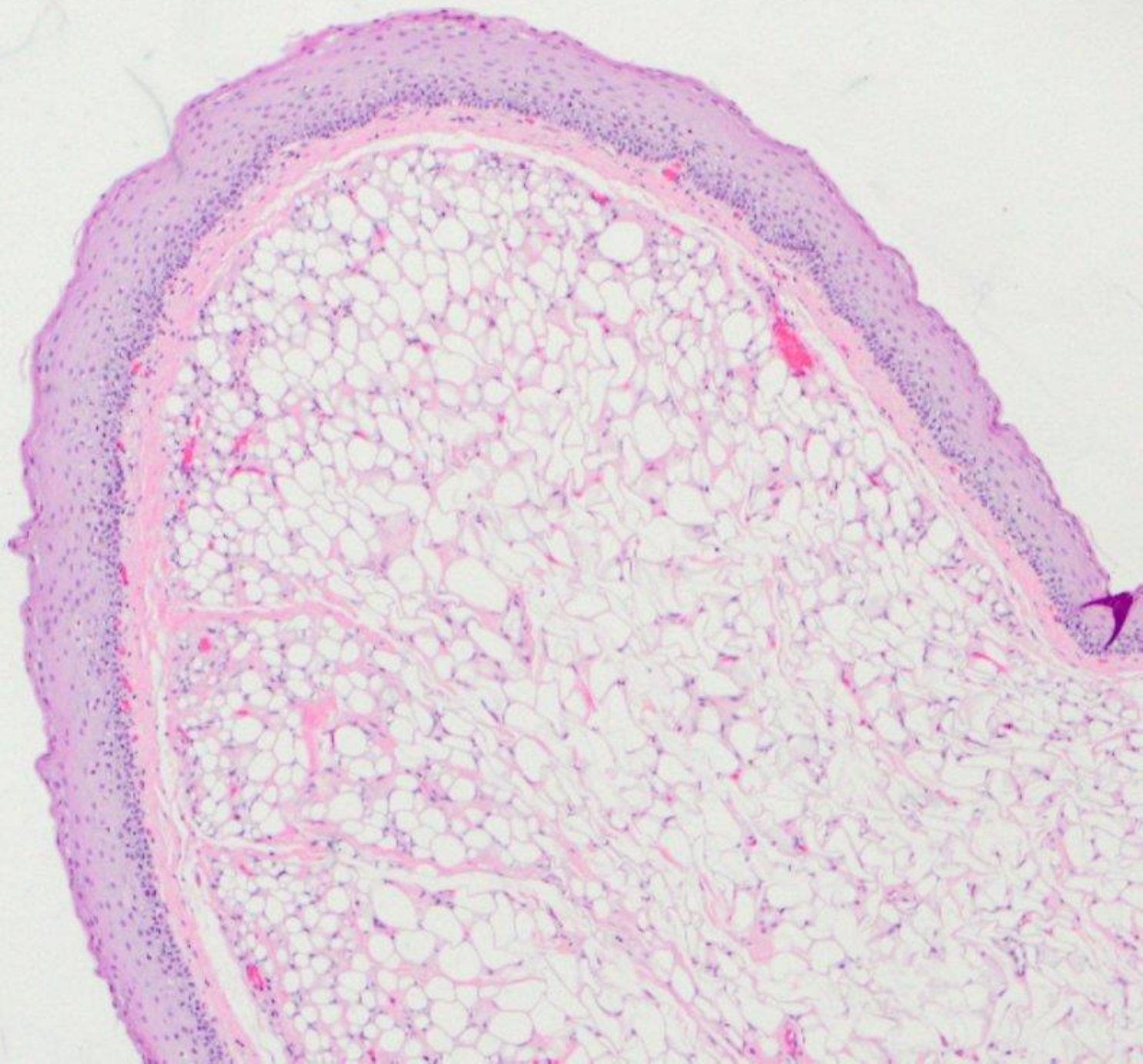


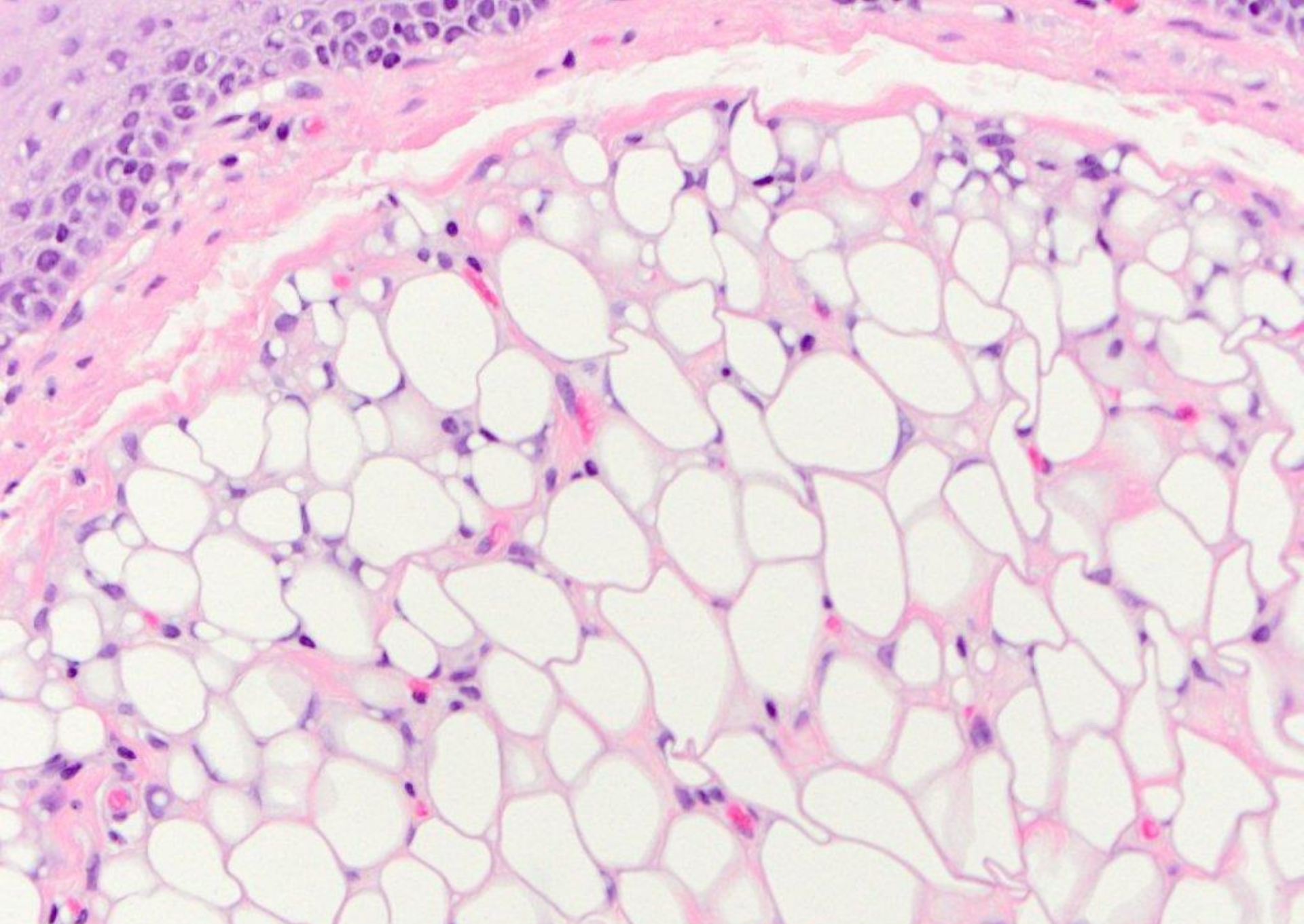




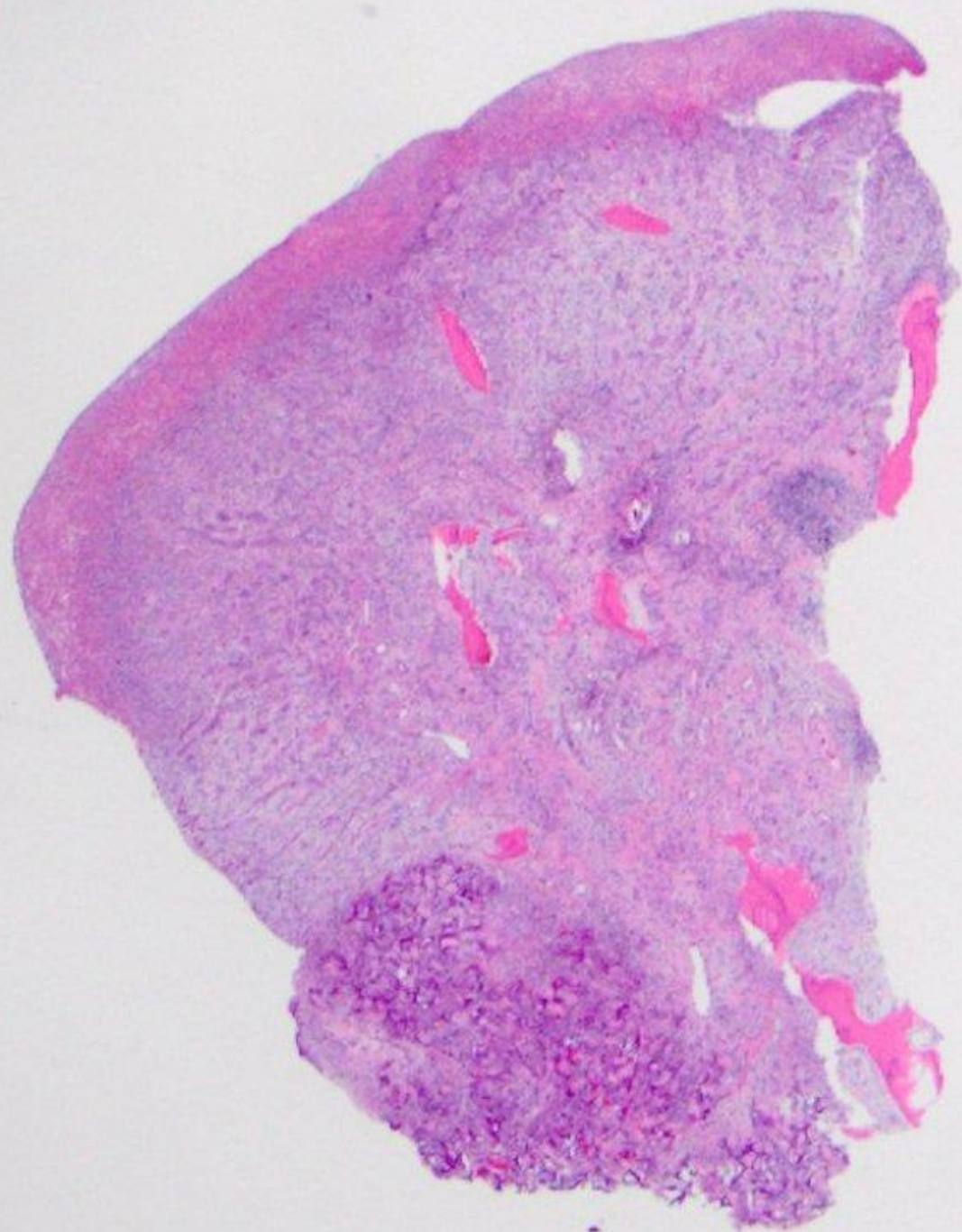
ulcerated peripheral giant cell granuloma with calcification

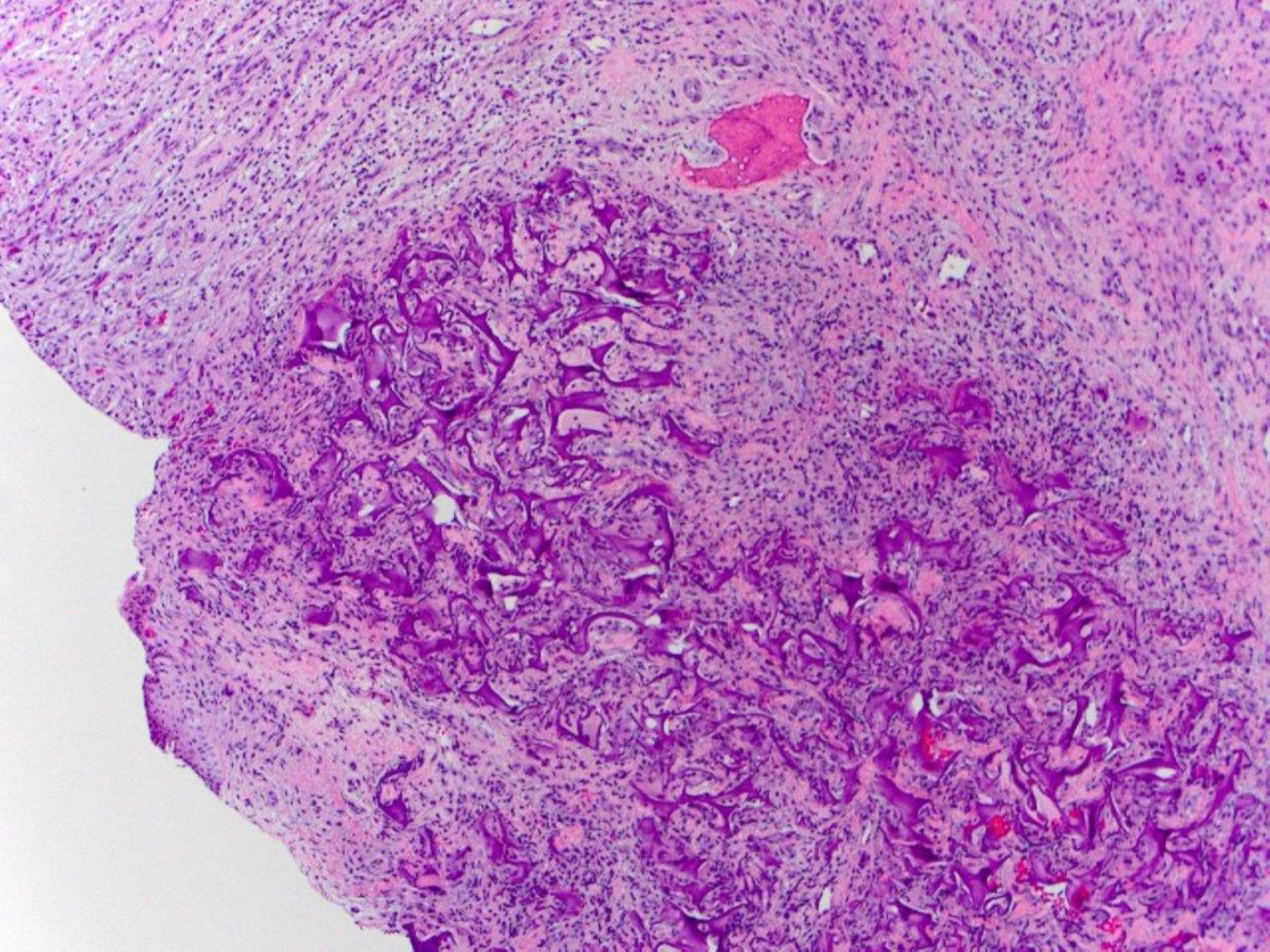


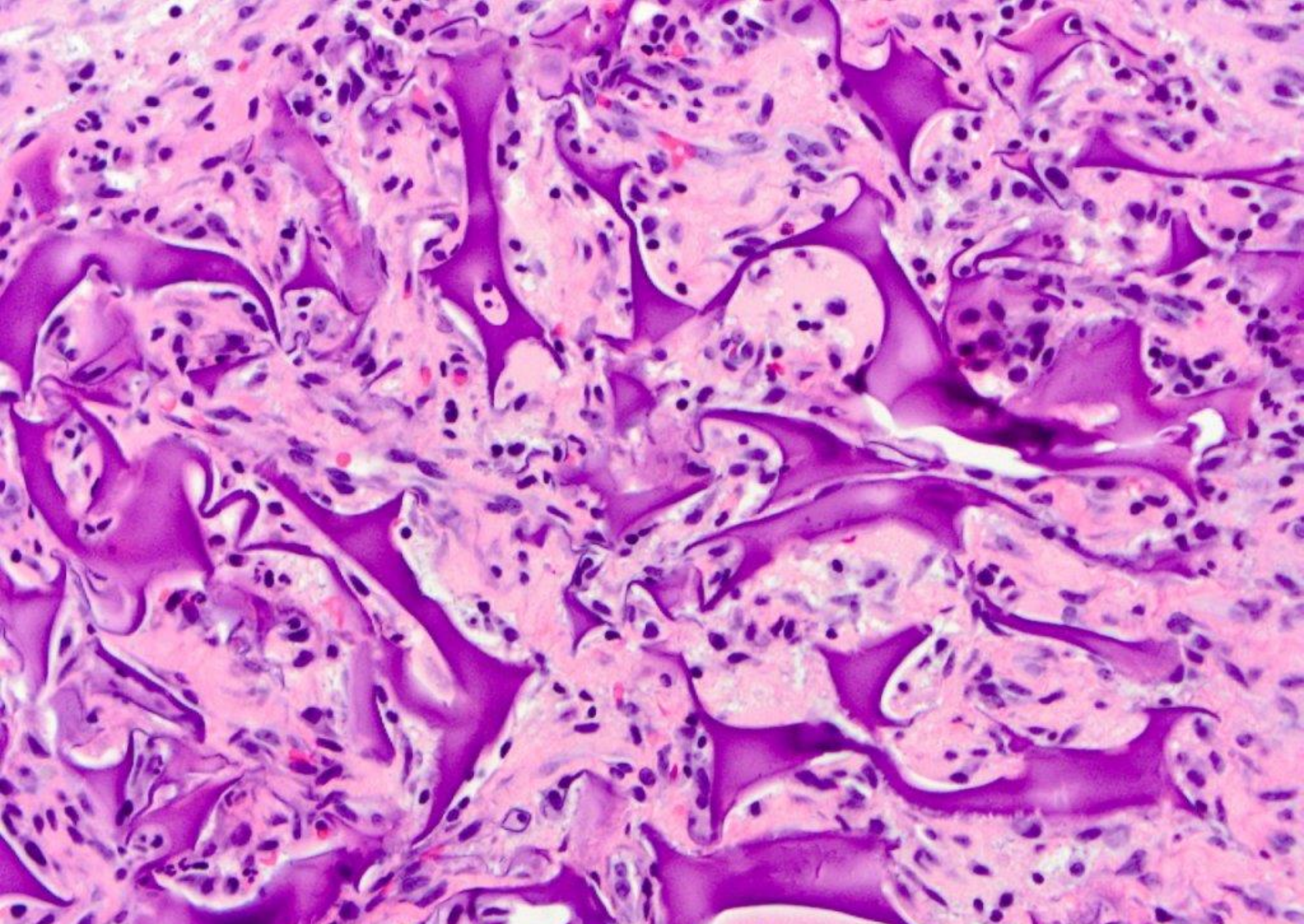




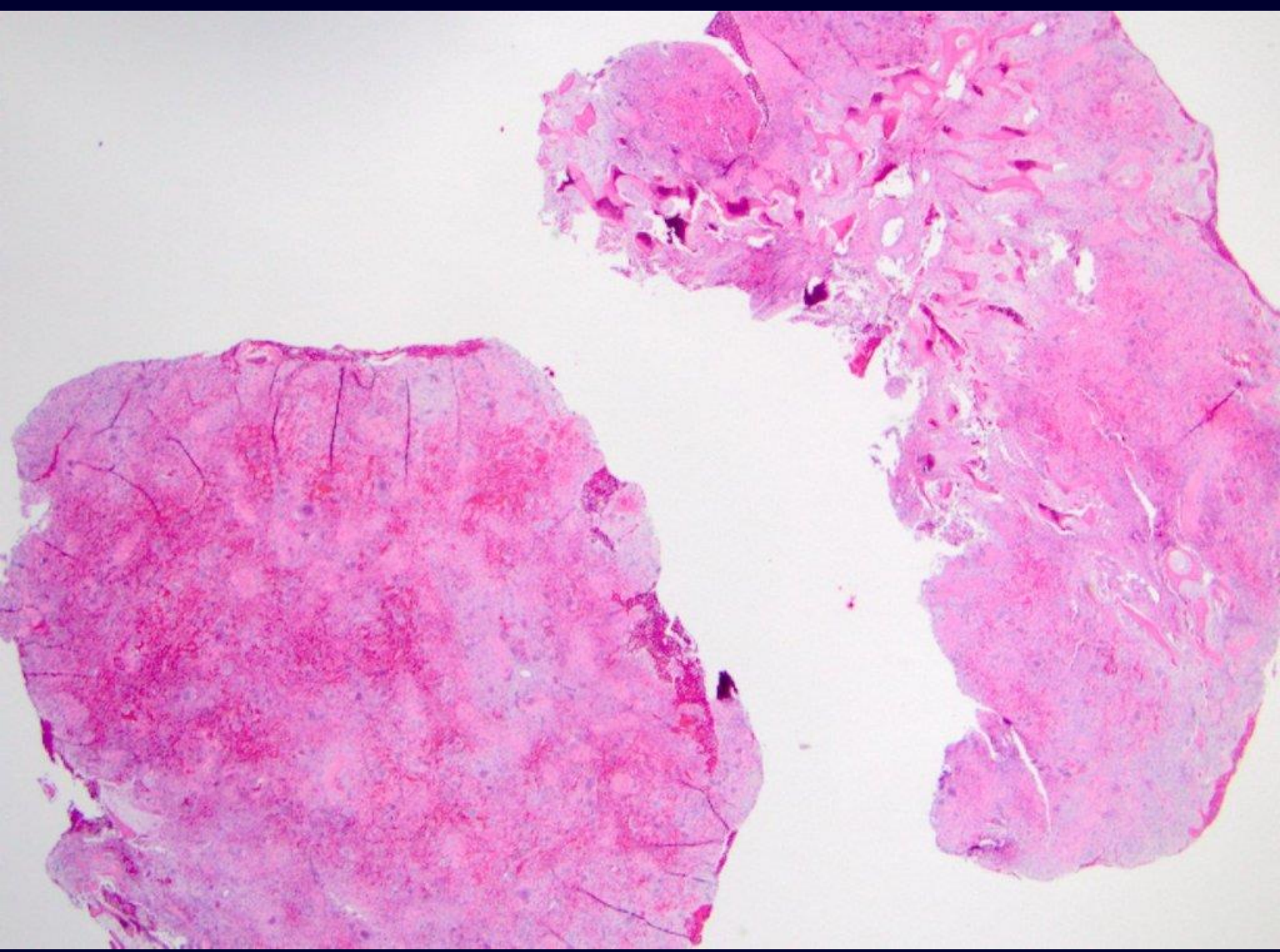
lipoma

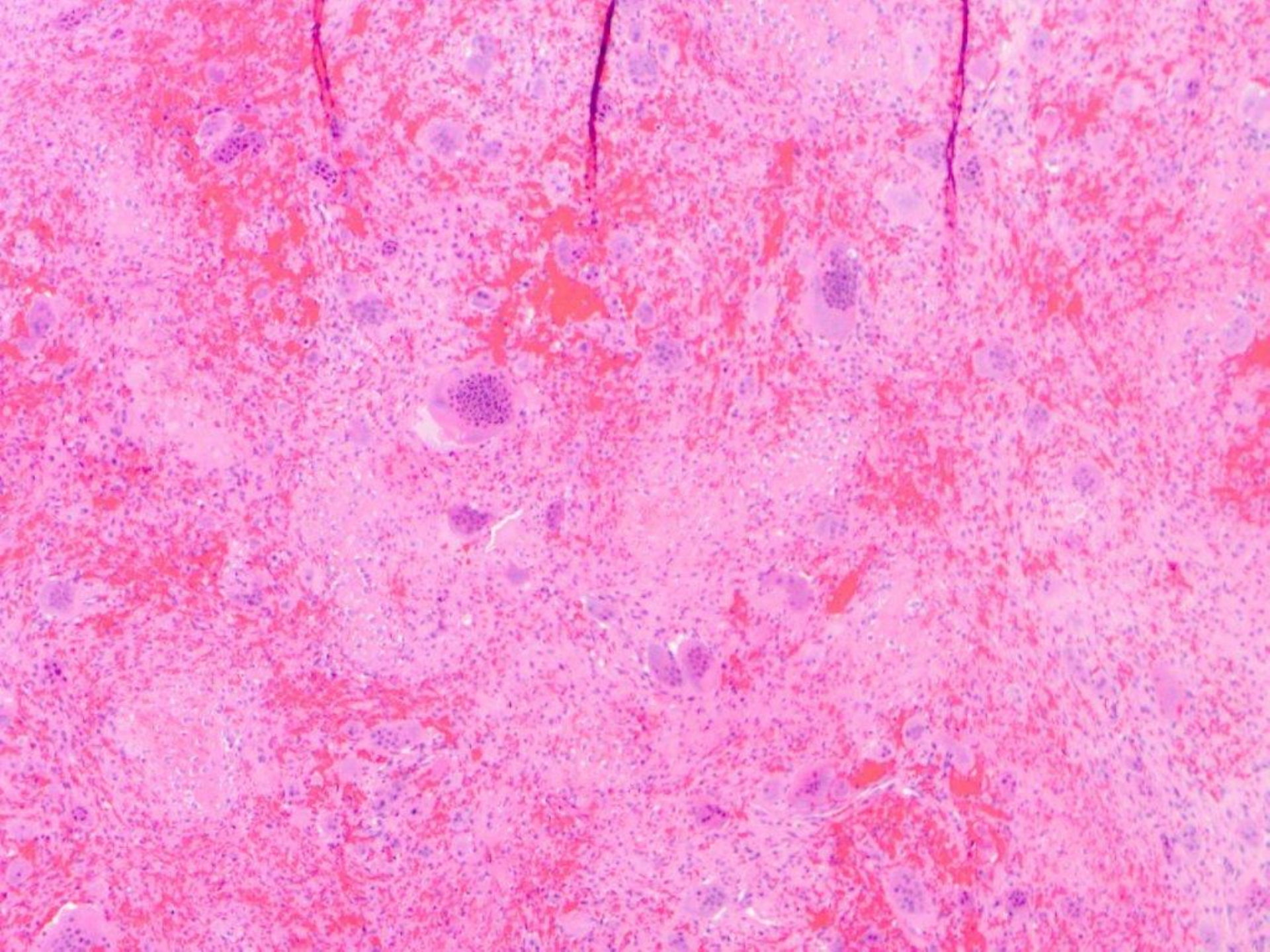


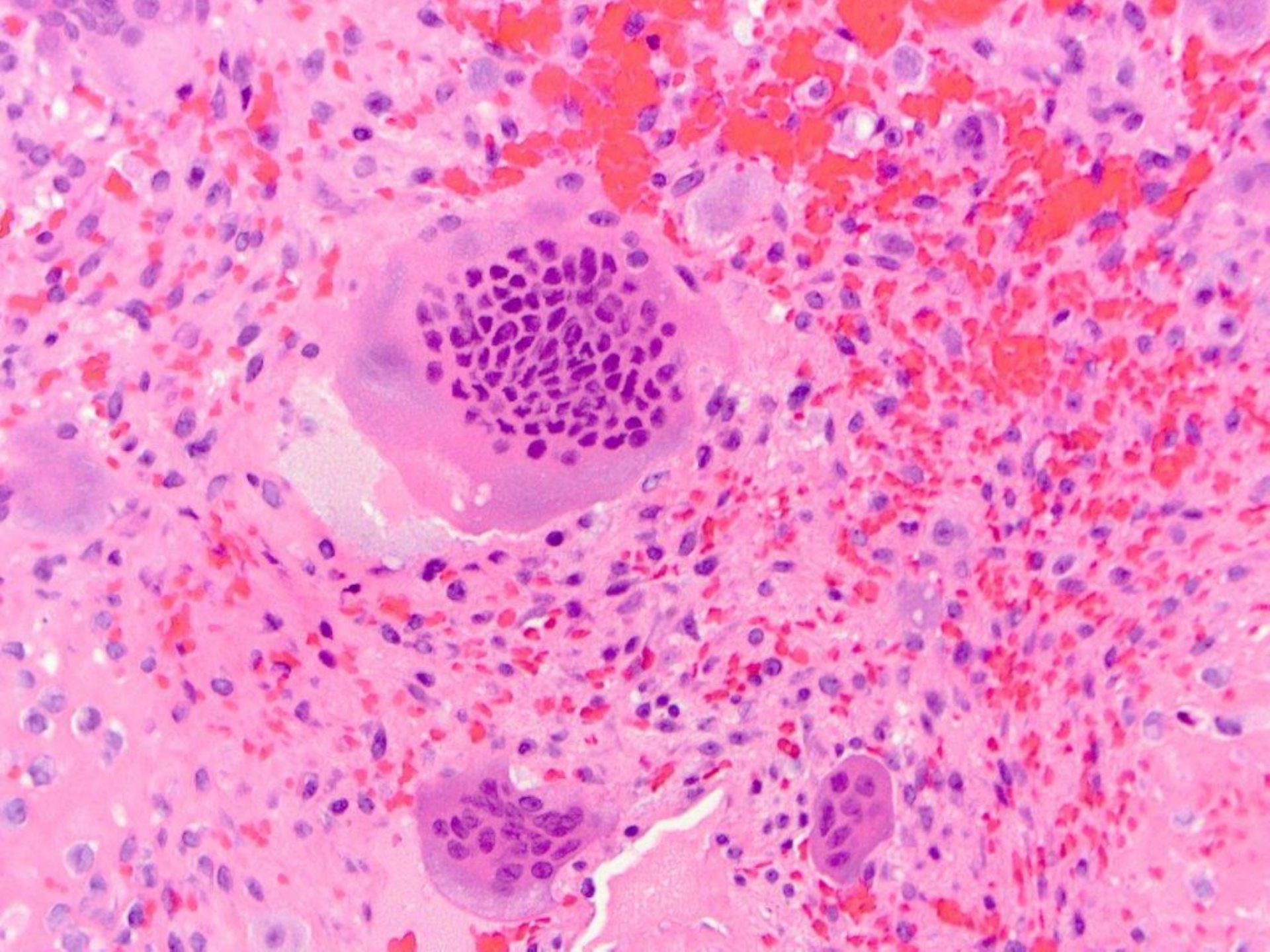


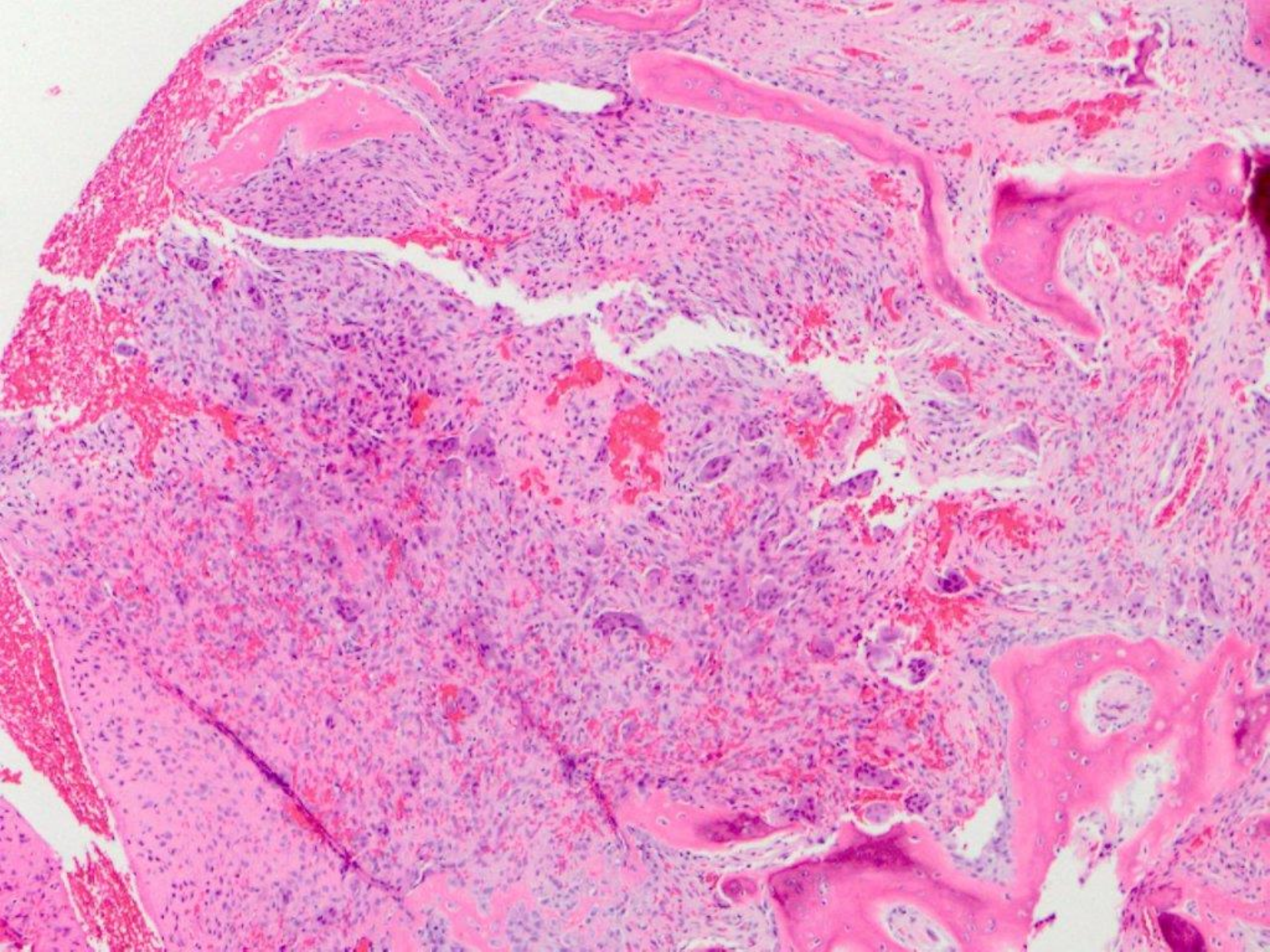


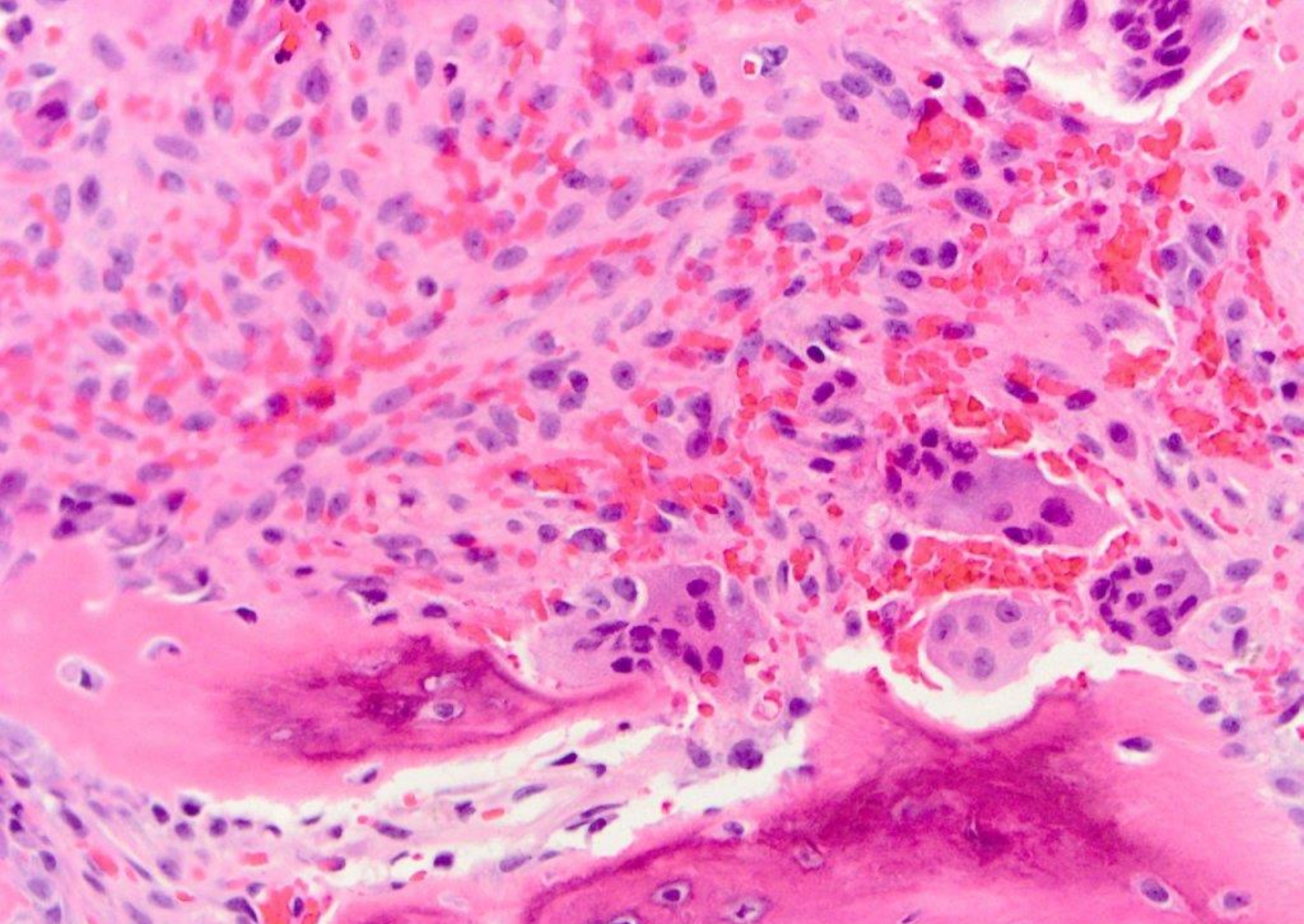
granulation tissue and Gelfoam



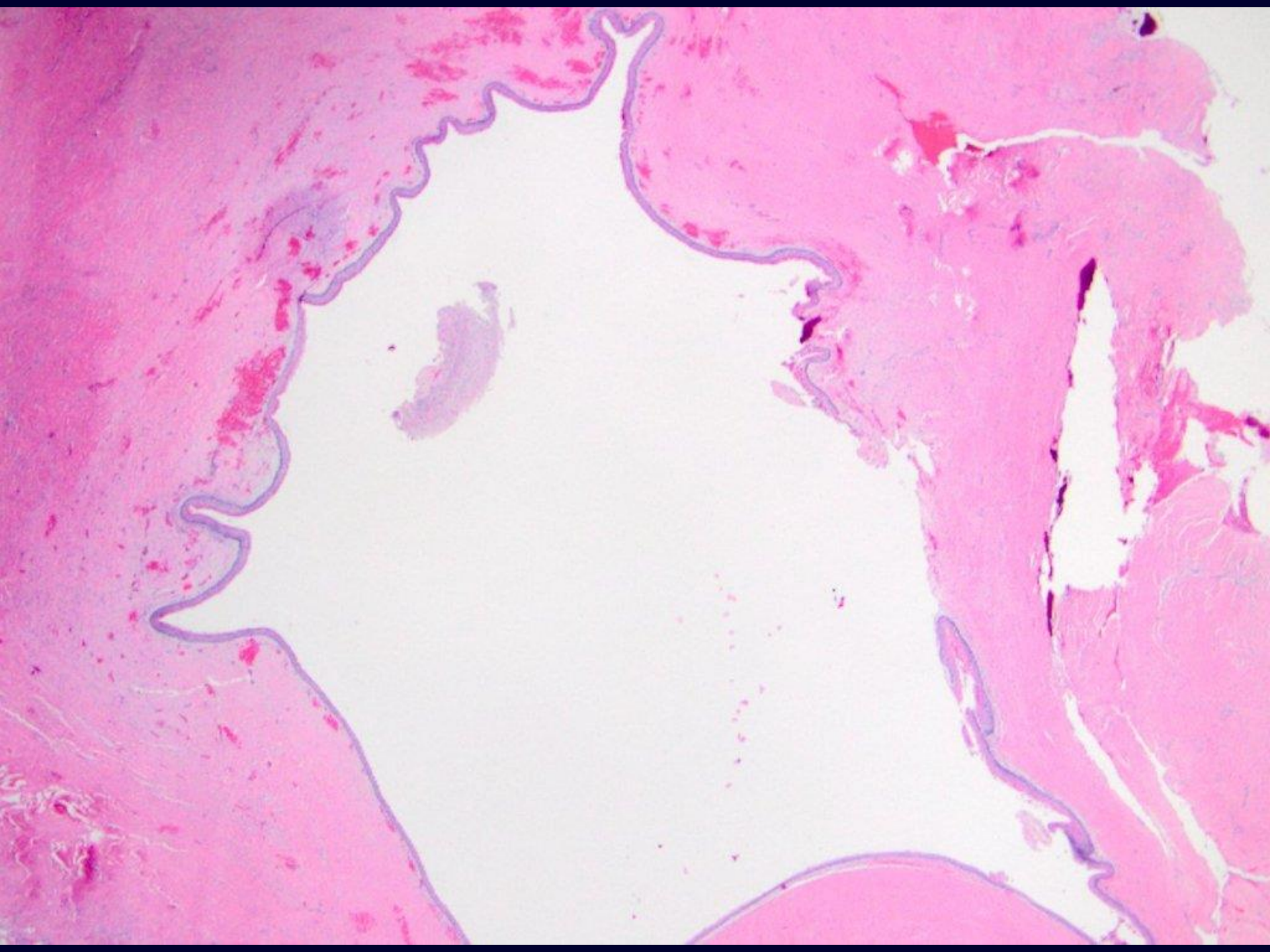


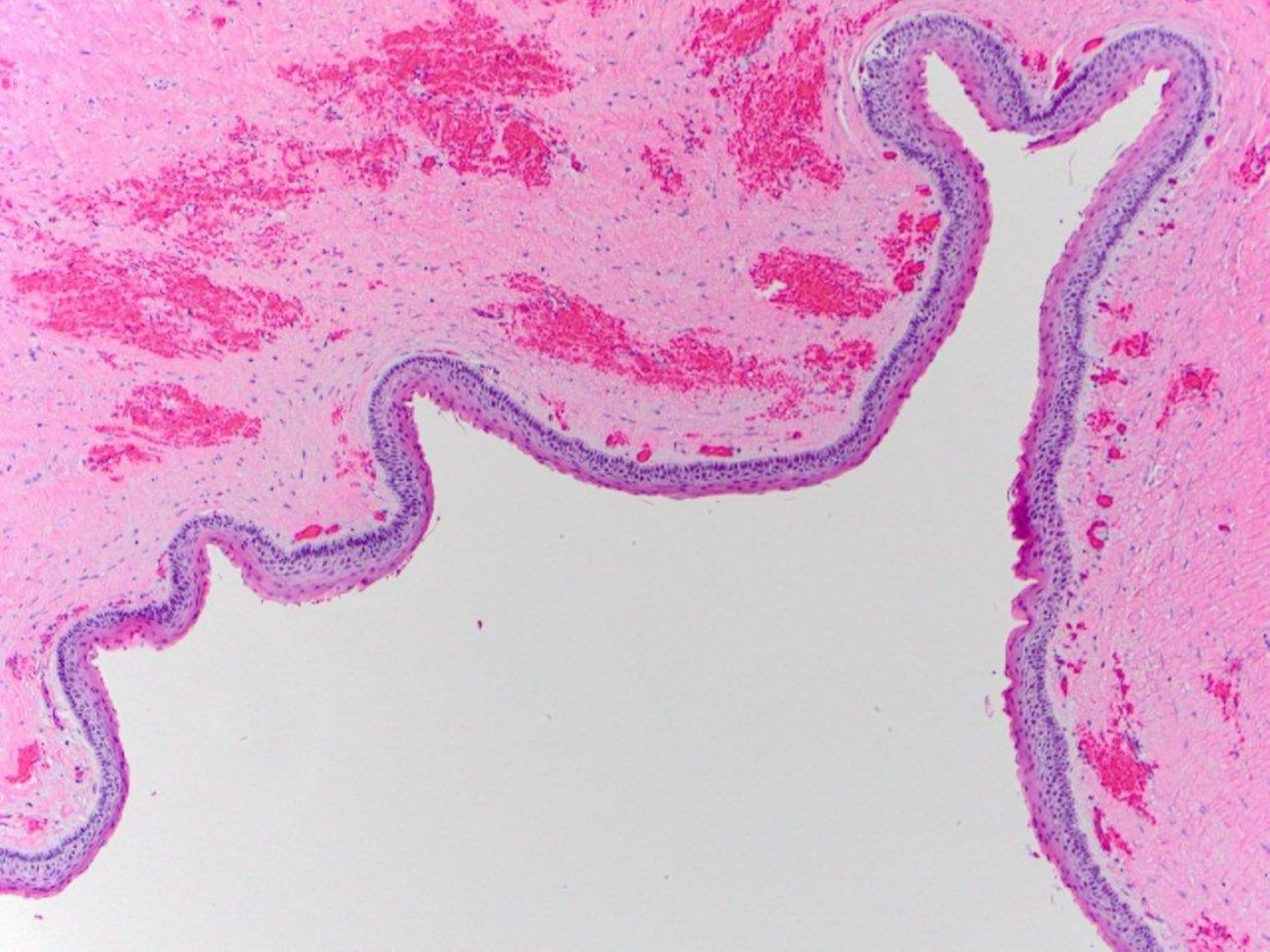


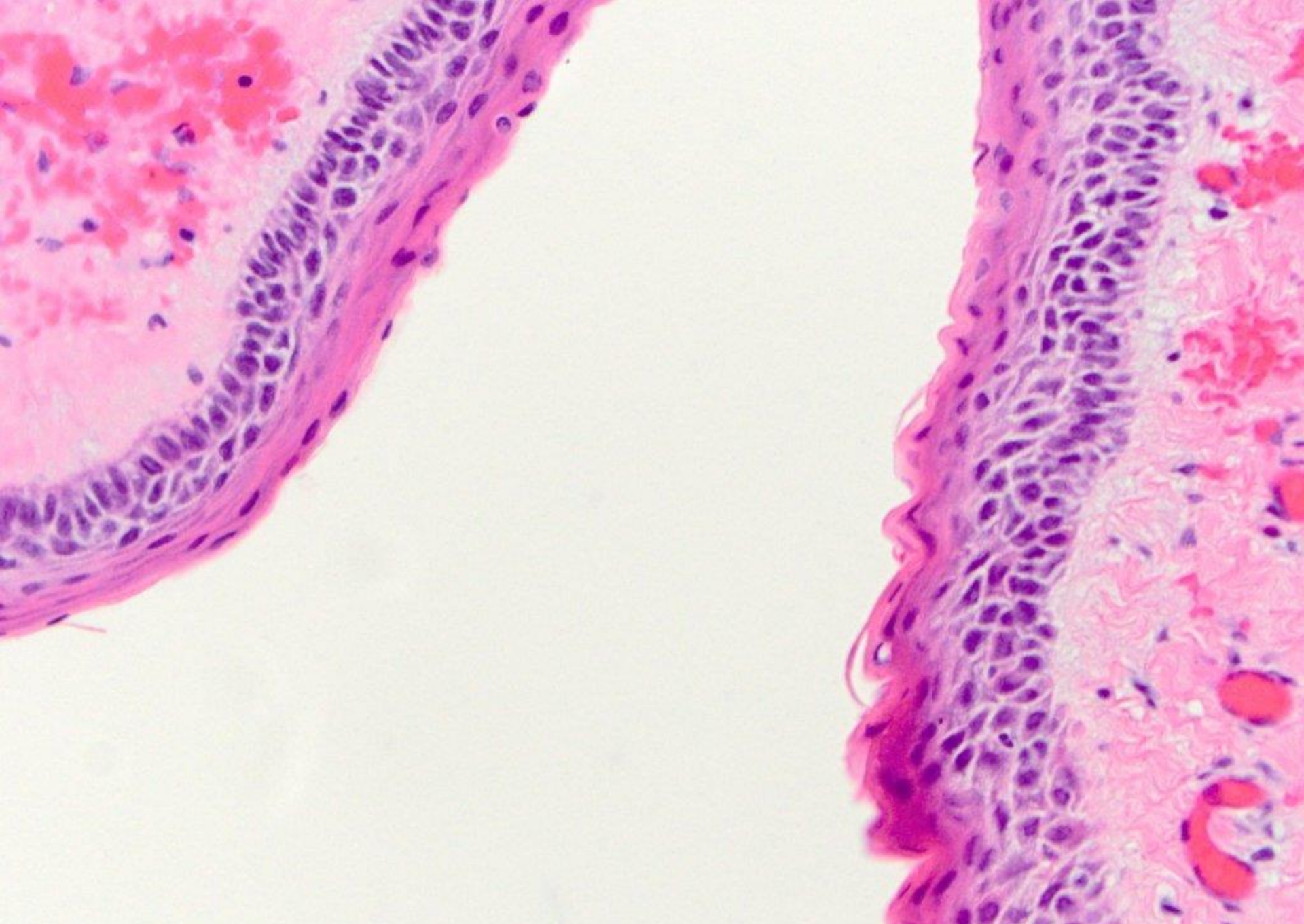




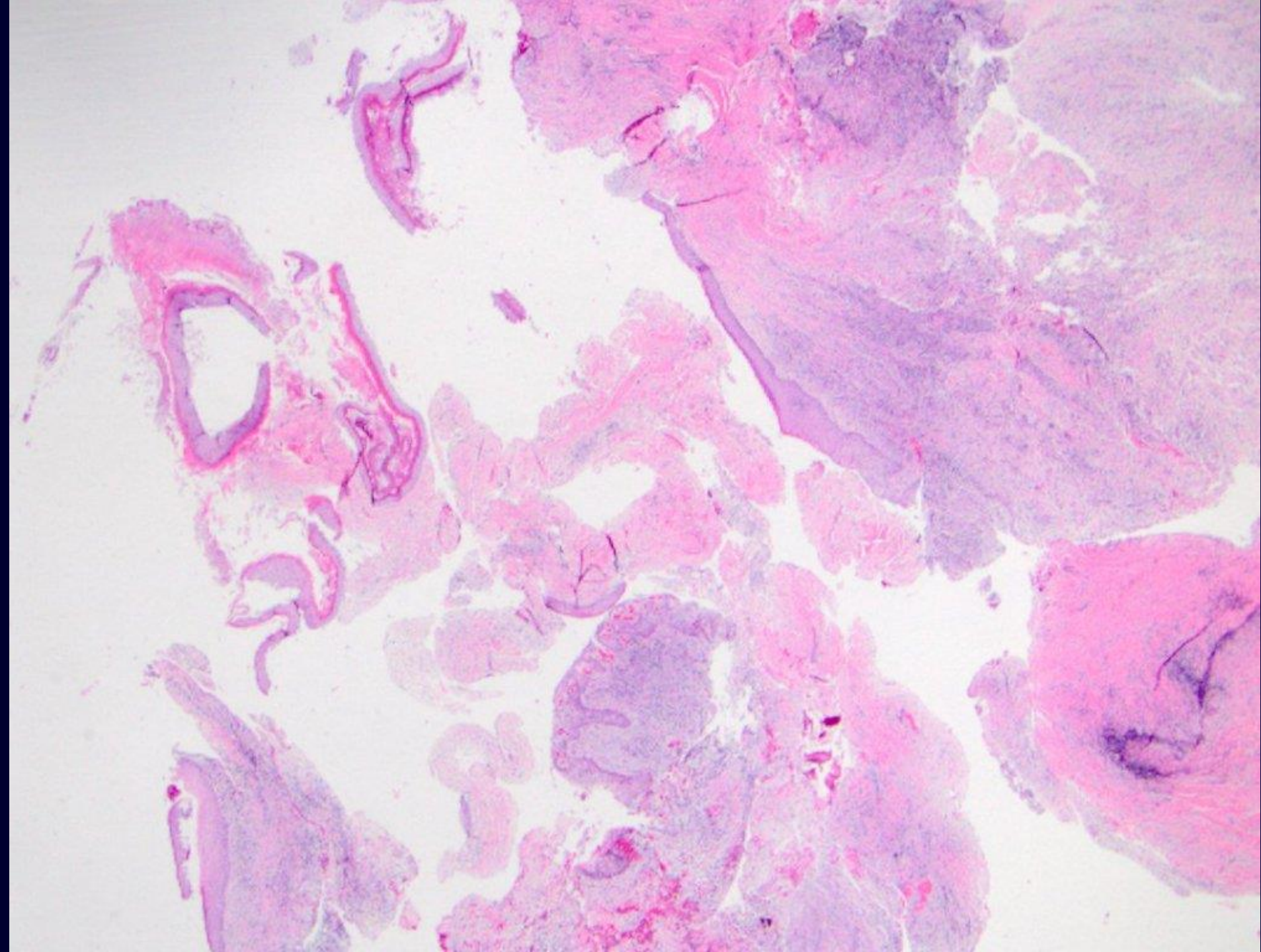
central giant cell granuloma

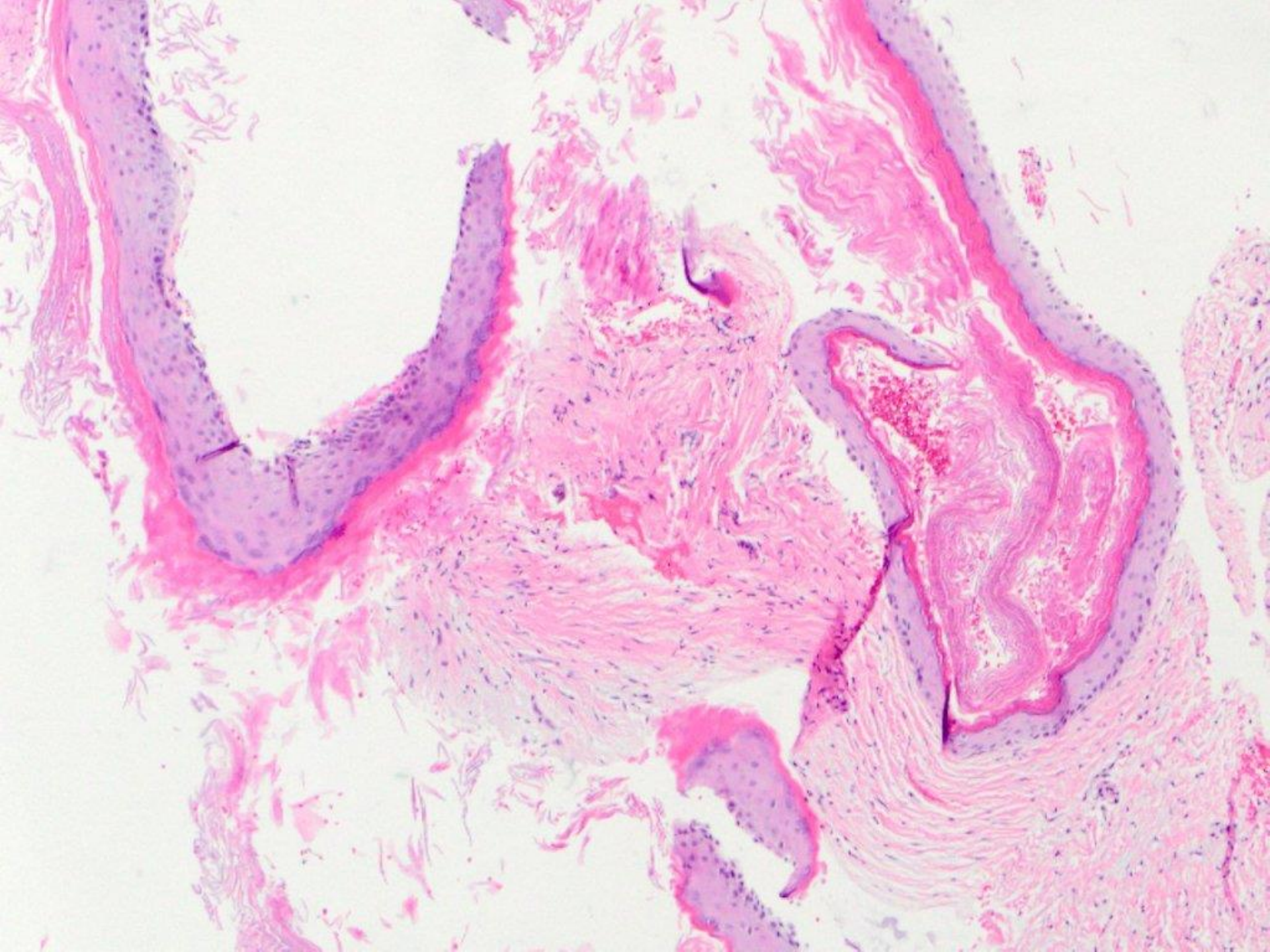


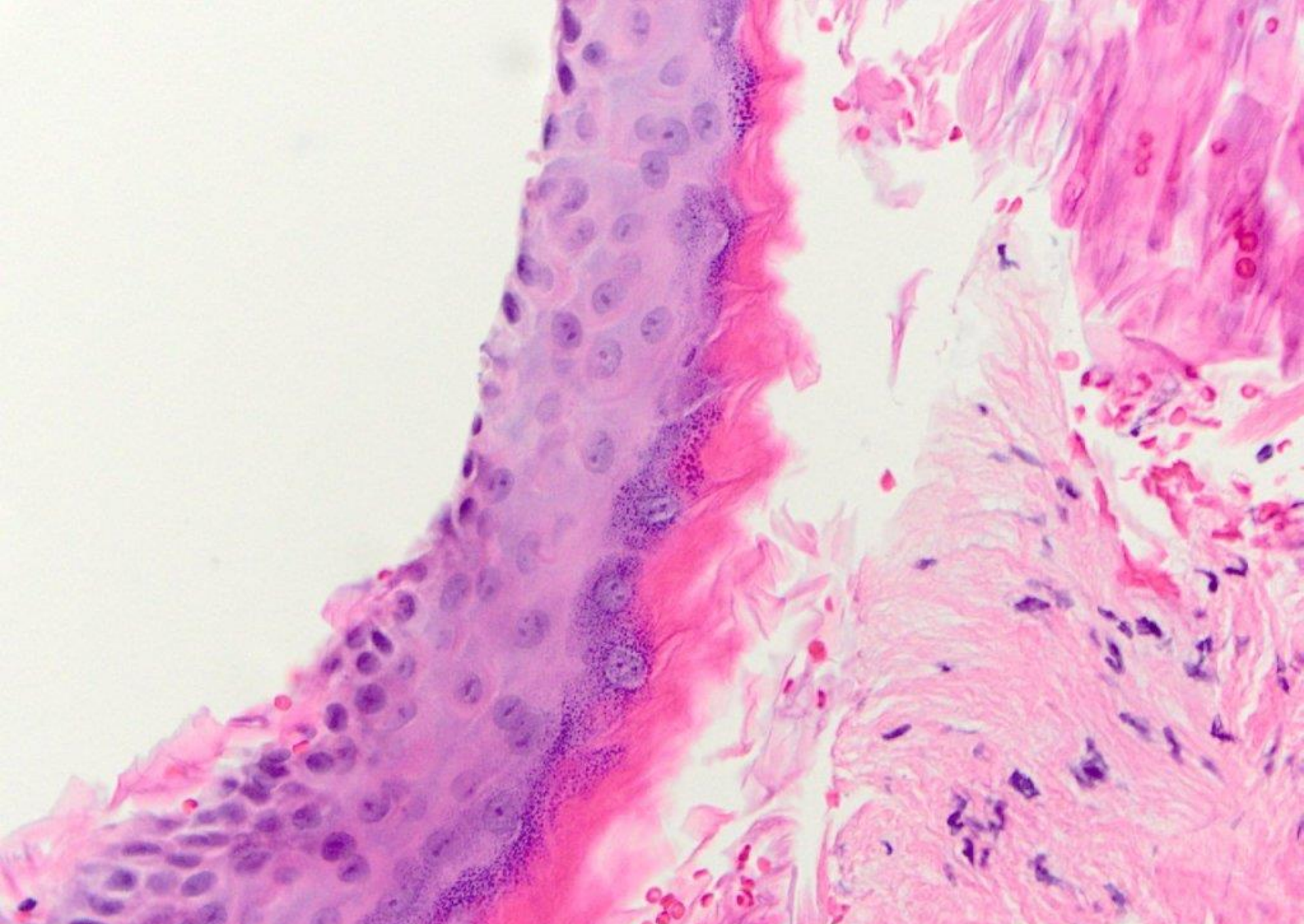




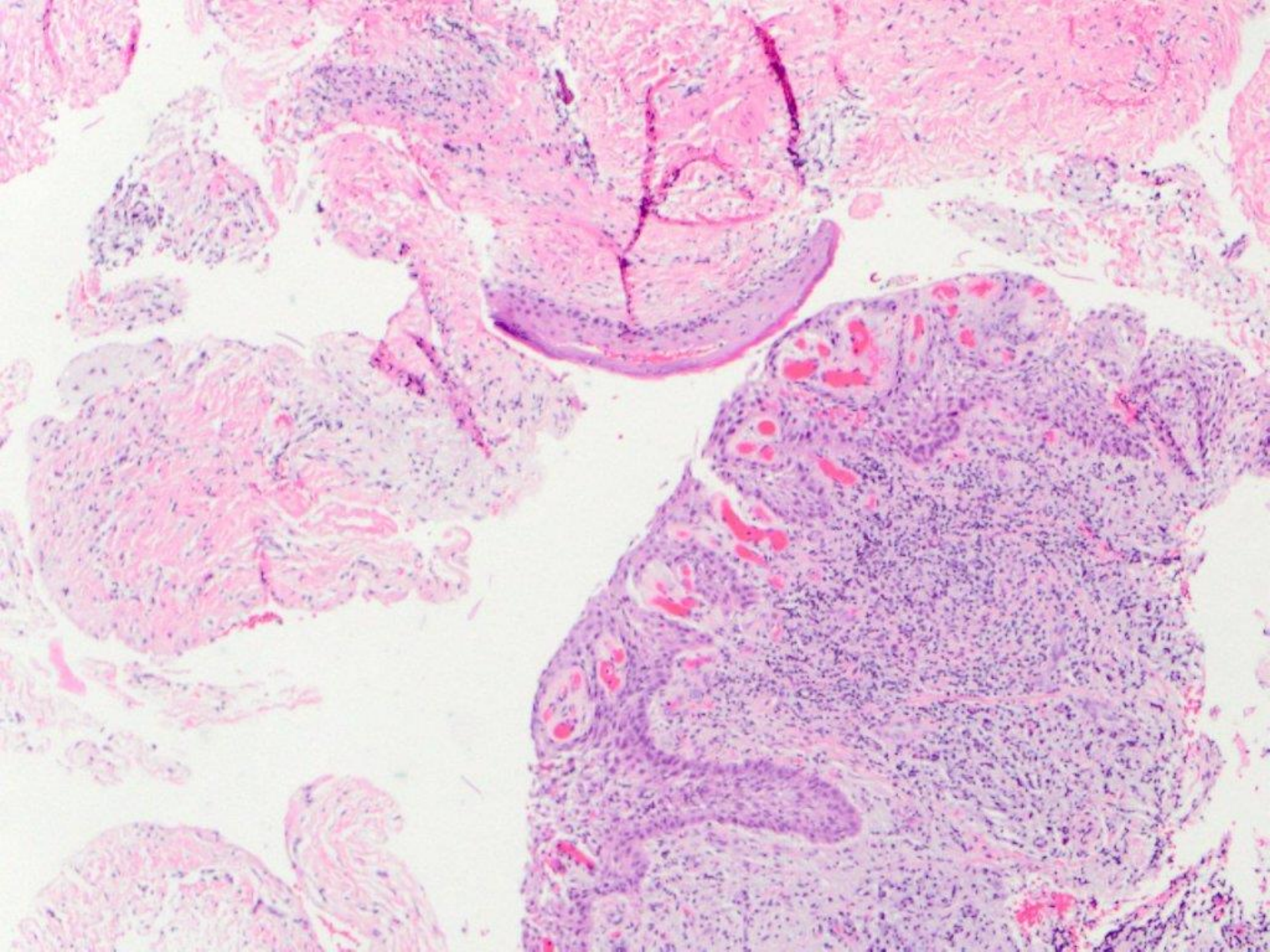
odontogenic keratocyst (keratocystic odontogenic tumor)

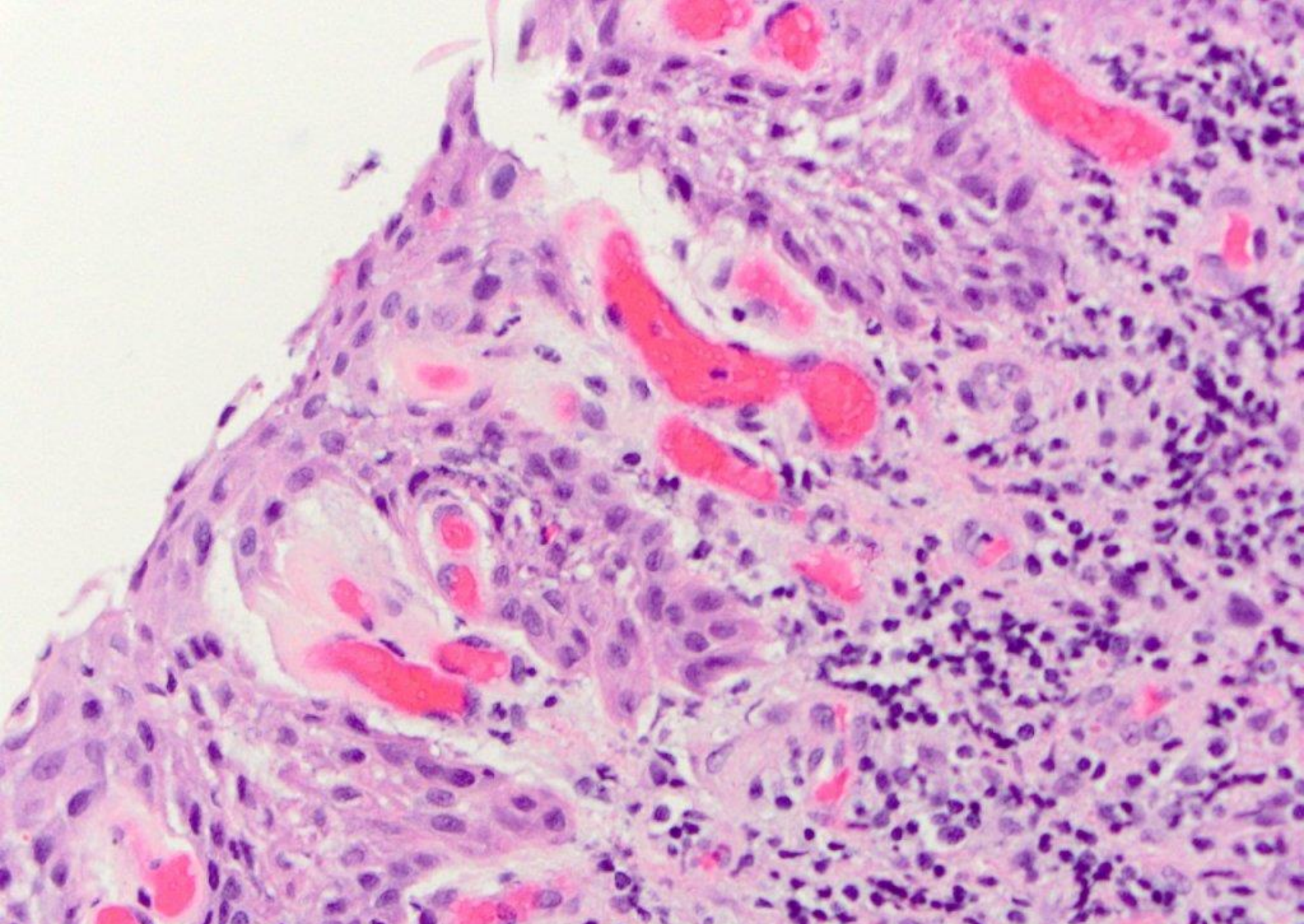






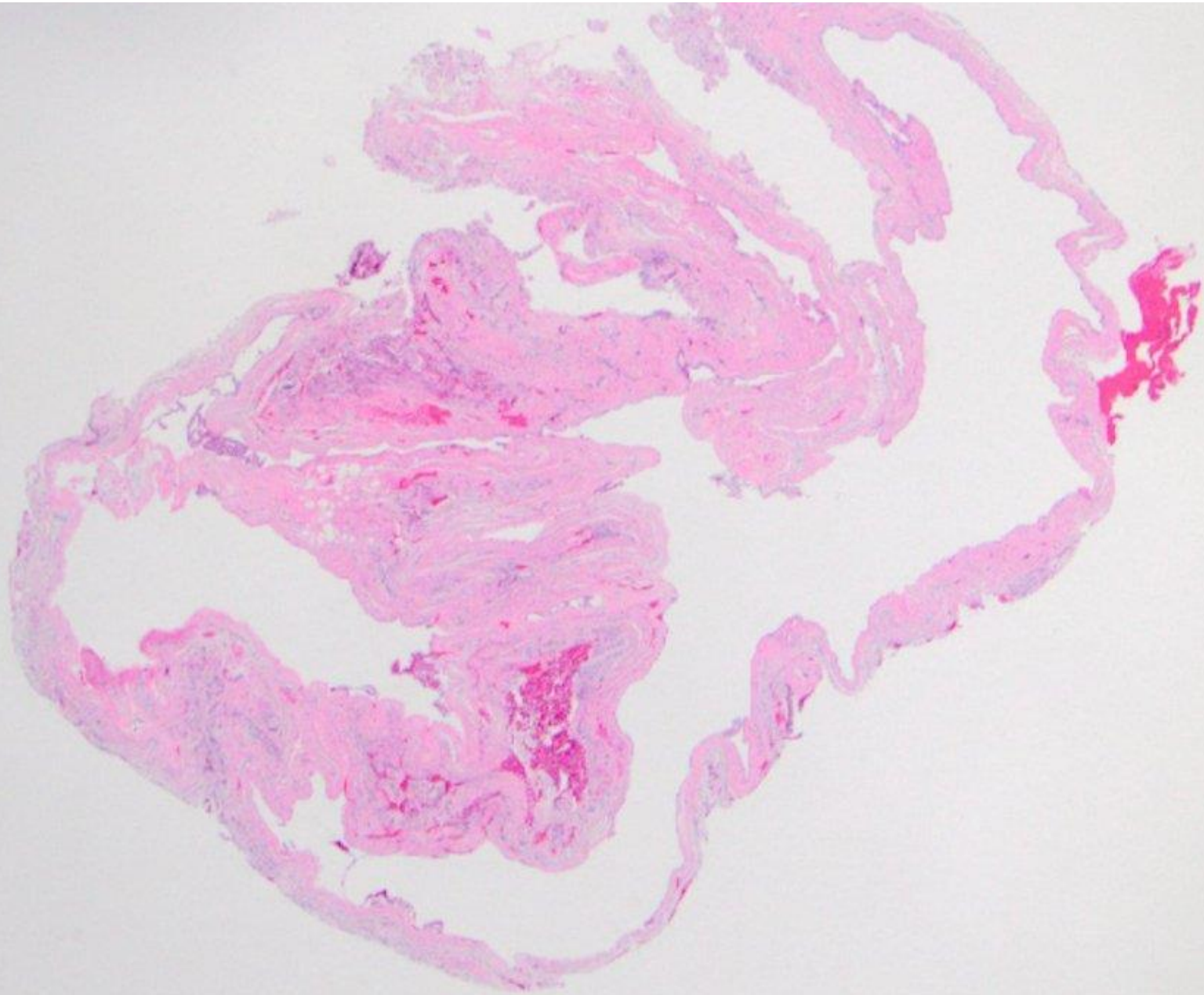
orthokeratinized odontogenic cyst

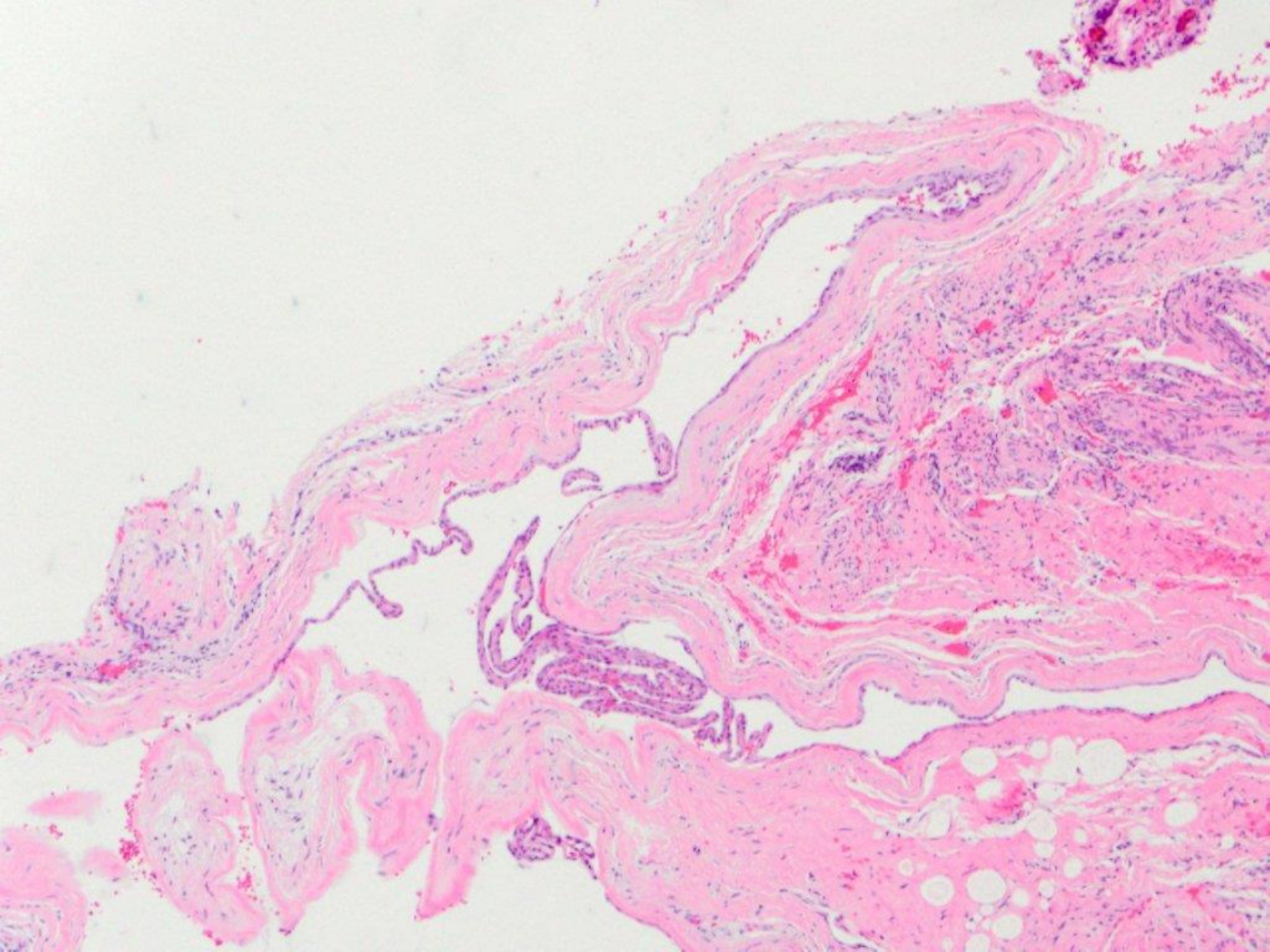


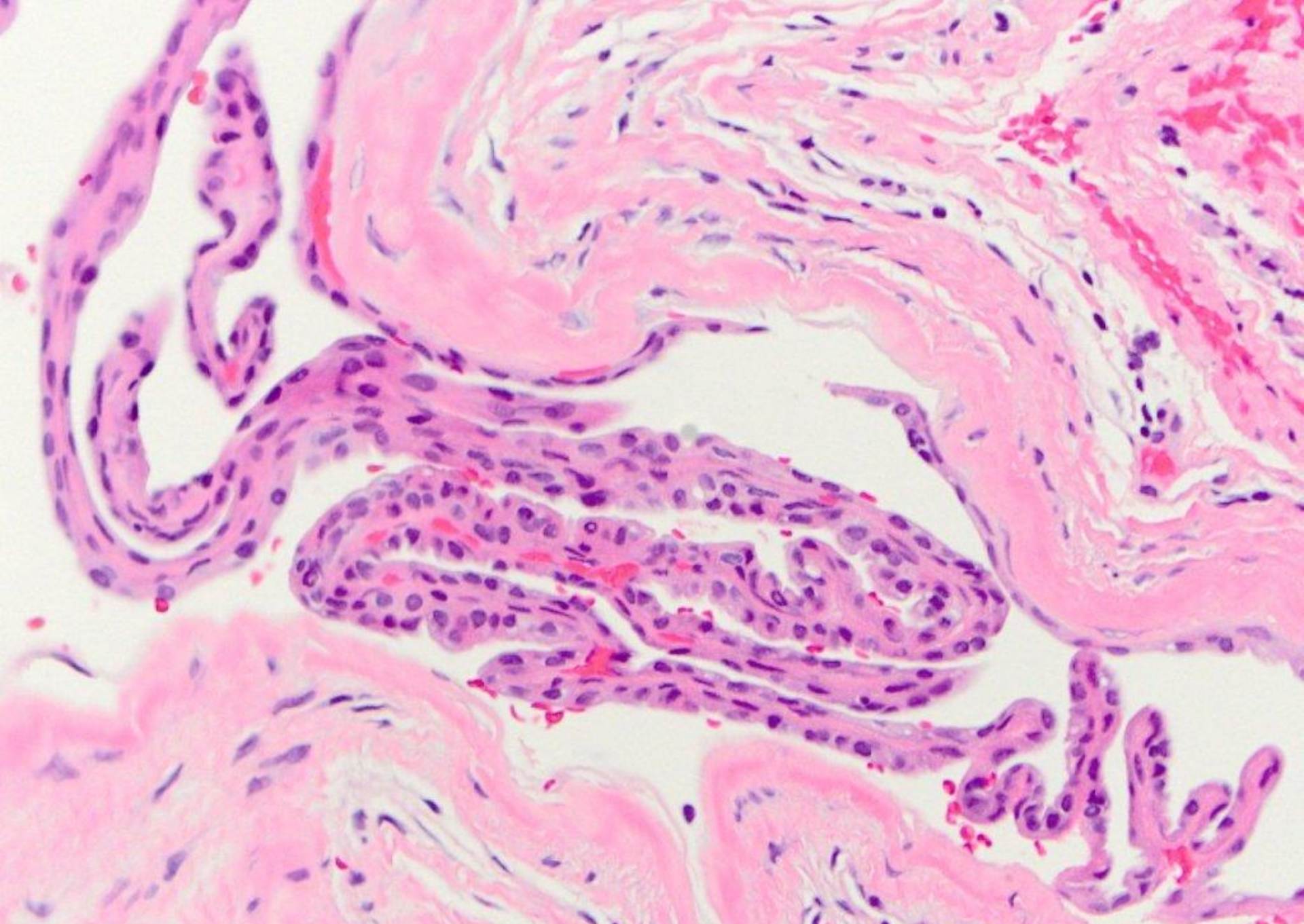


orthokeratinized odontogenic cyst (focally inflamed, characteristics lost)

clinically described on the lateral aspect of a mandibular bicuspid root

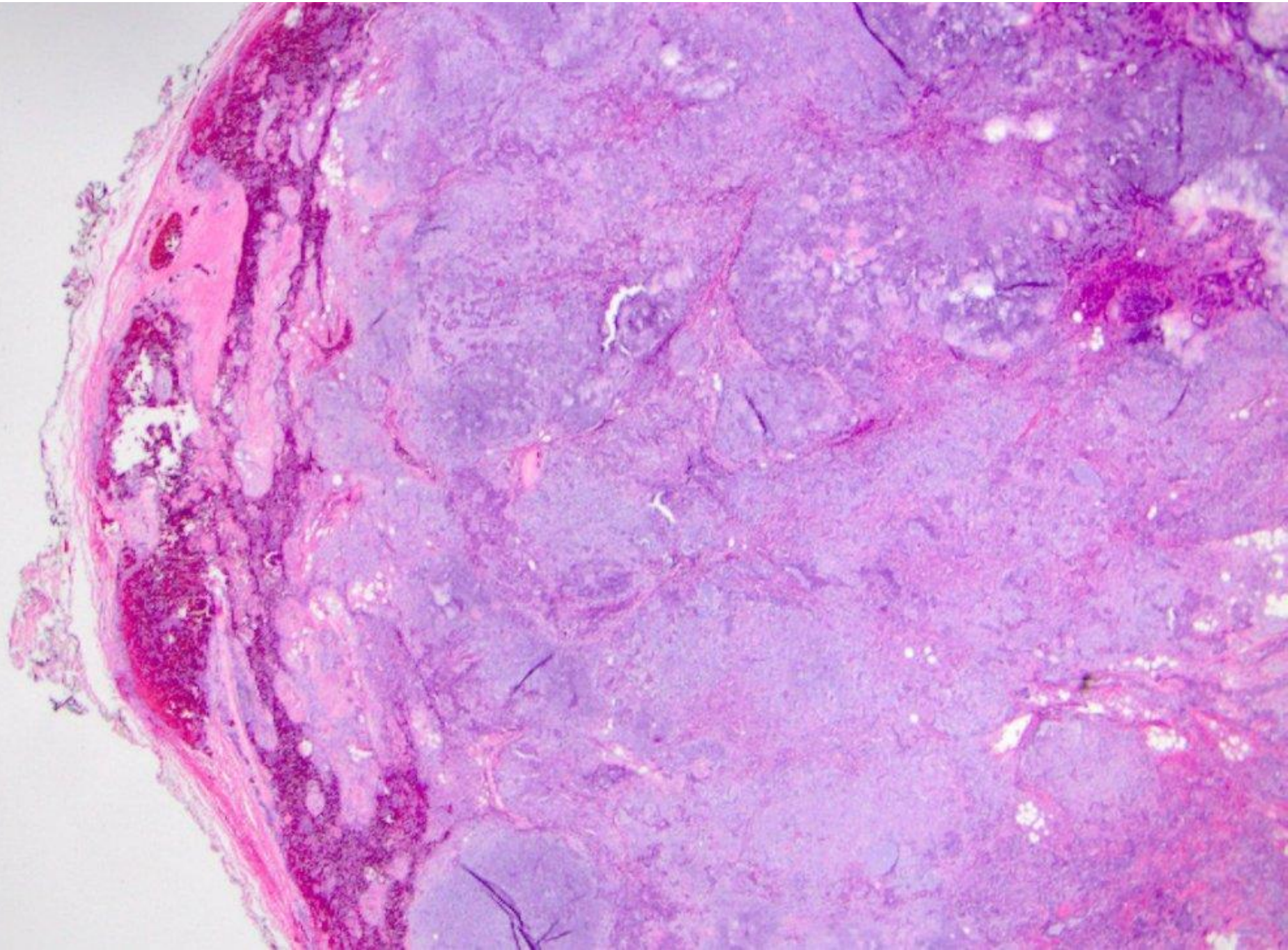


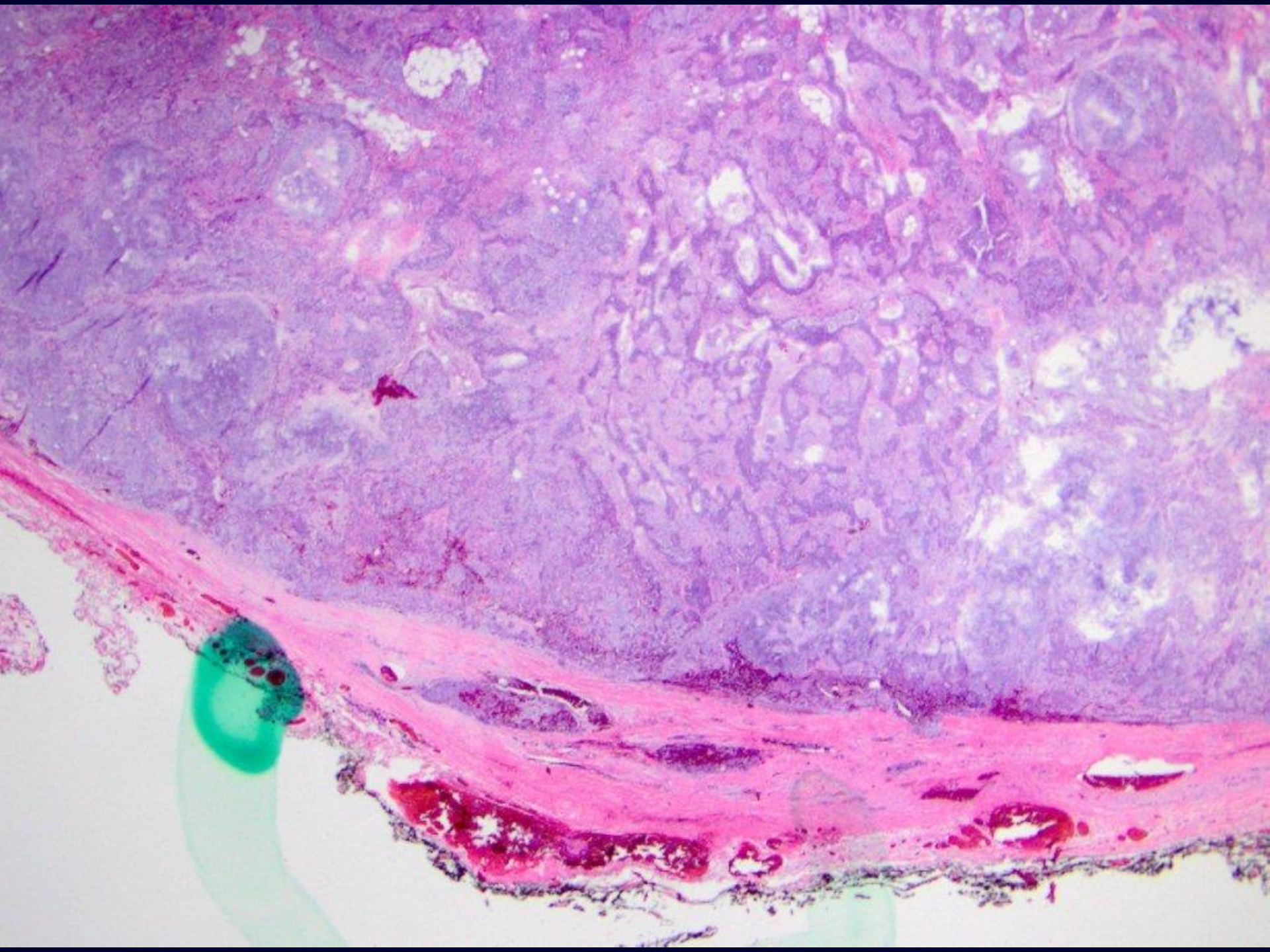


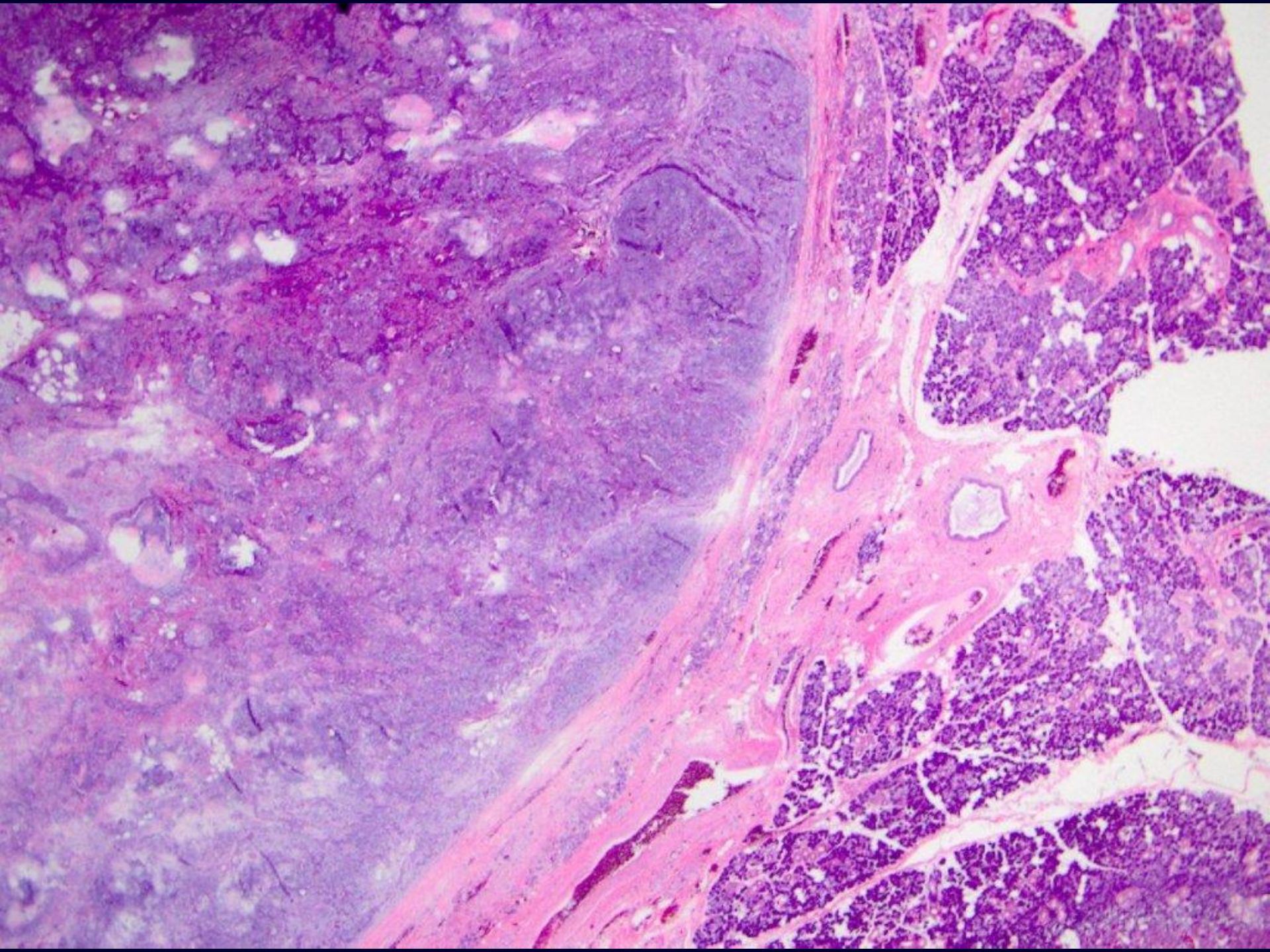


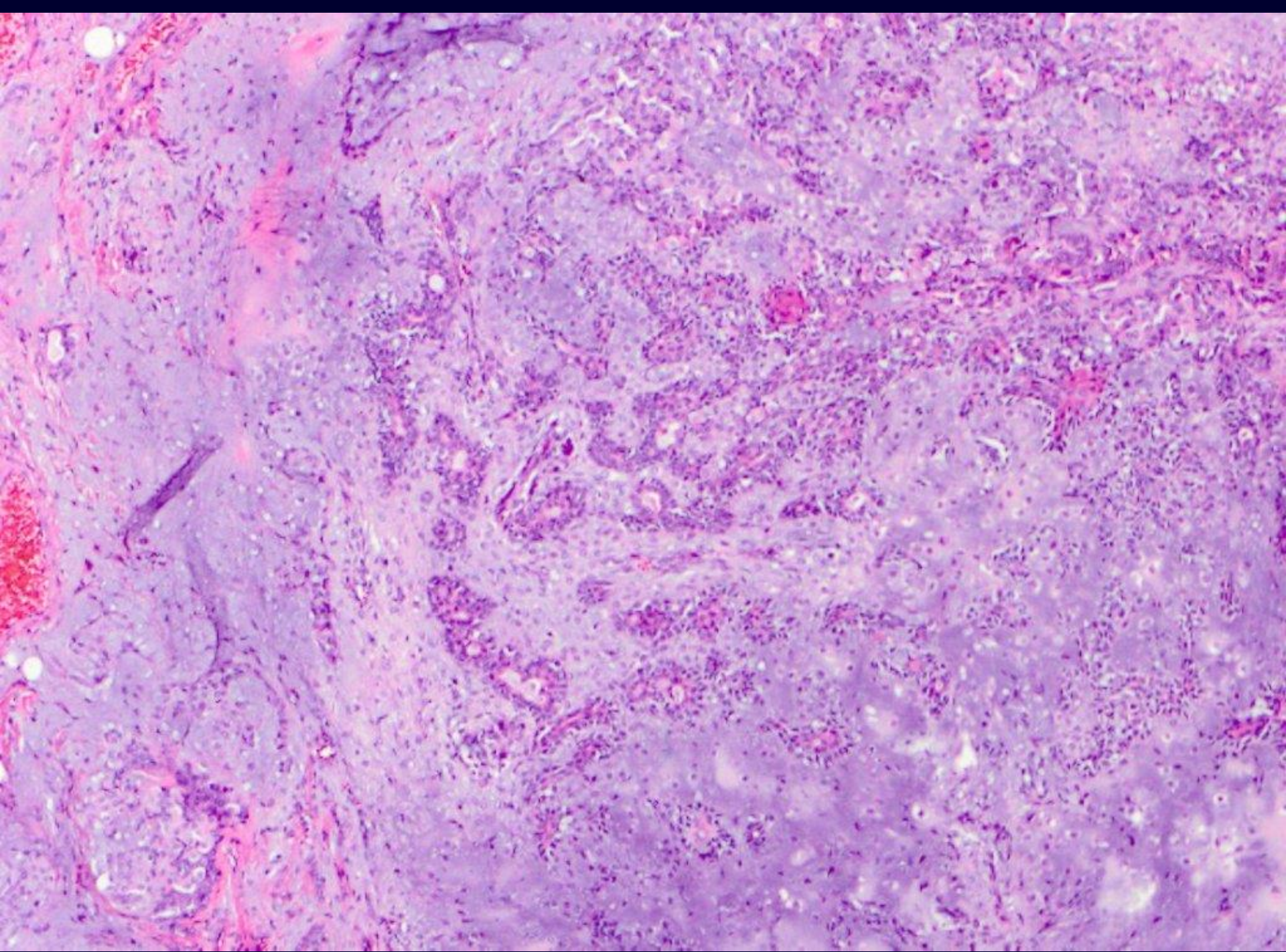
lateral periodontal cyst

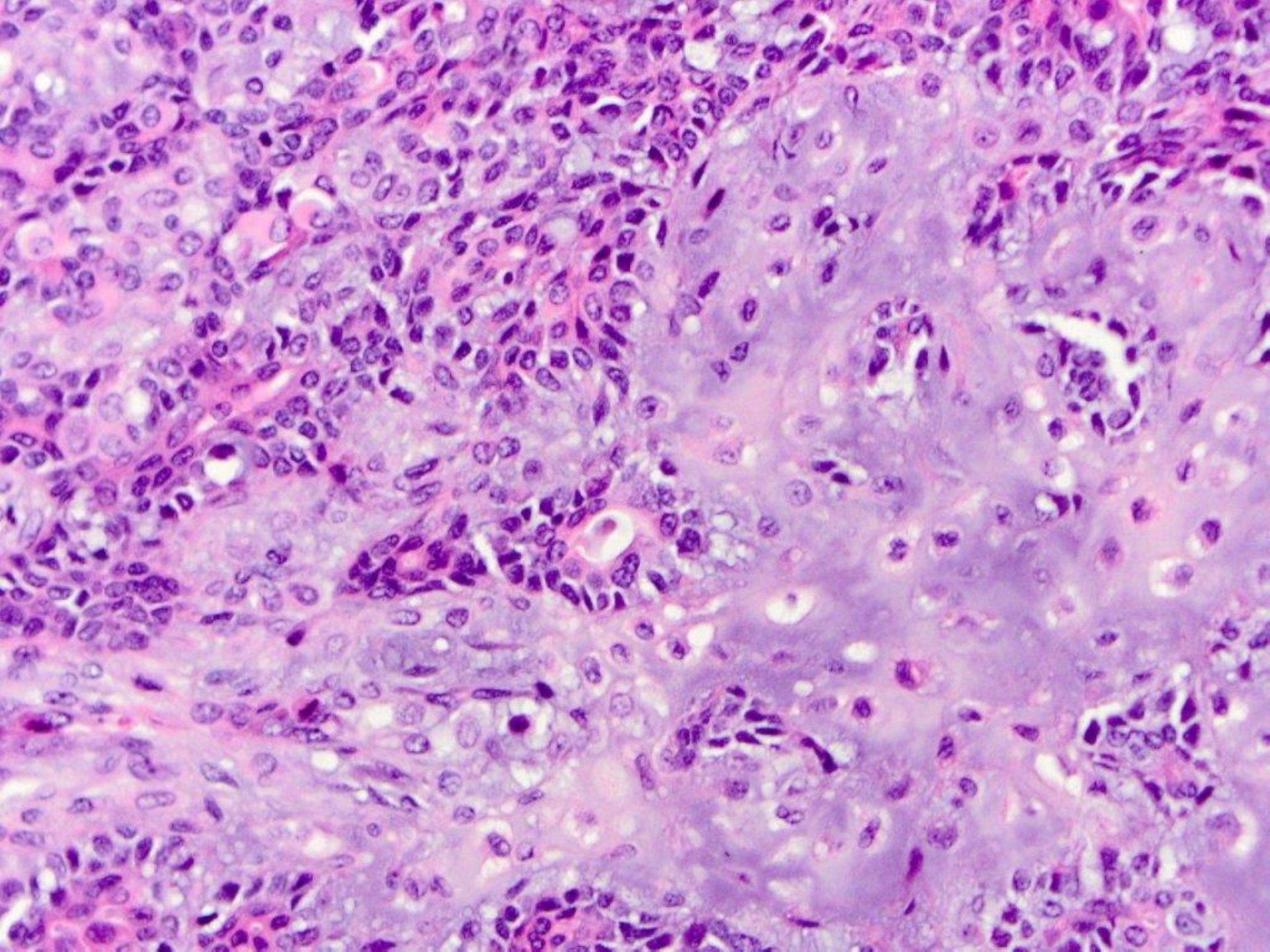
10yo male, submandibular tumor

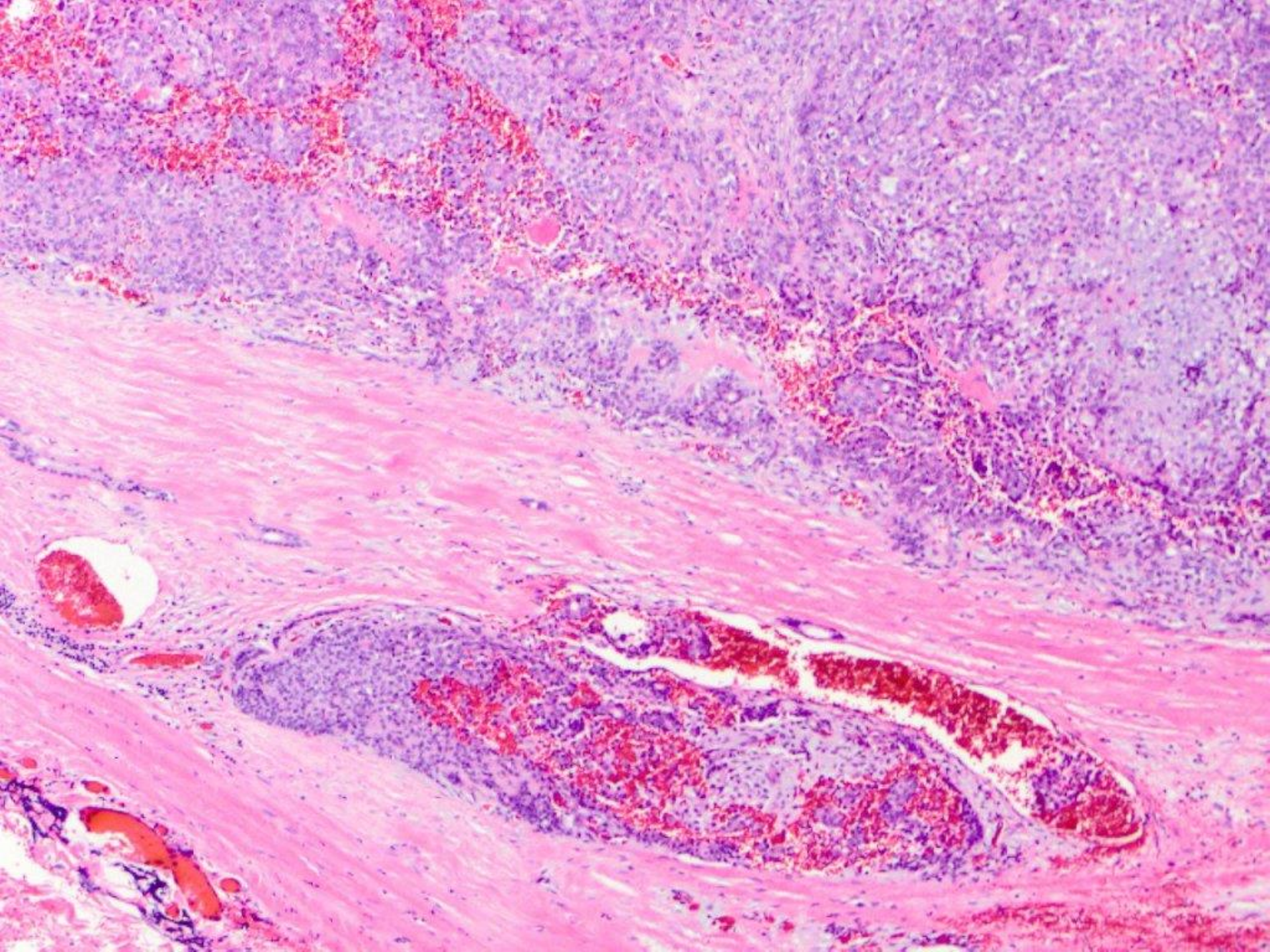


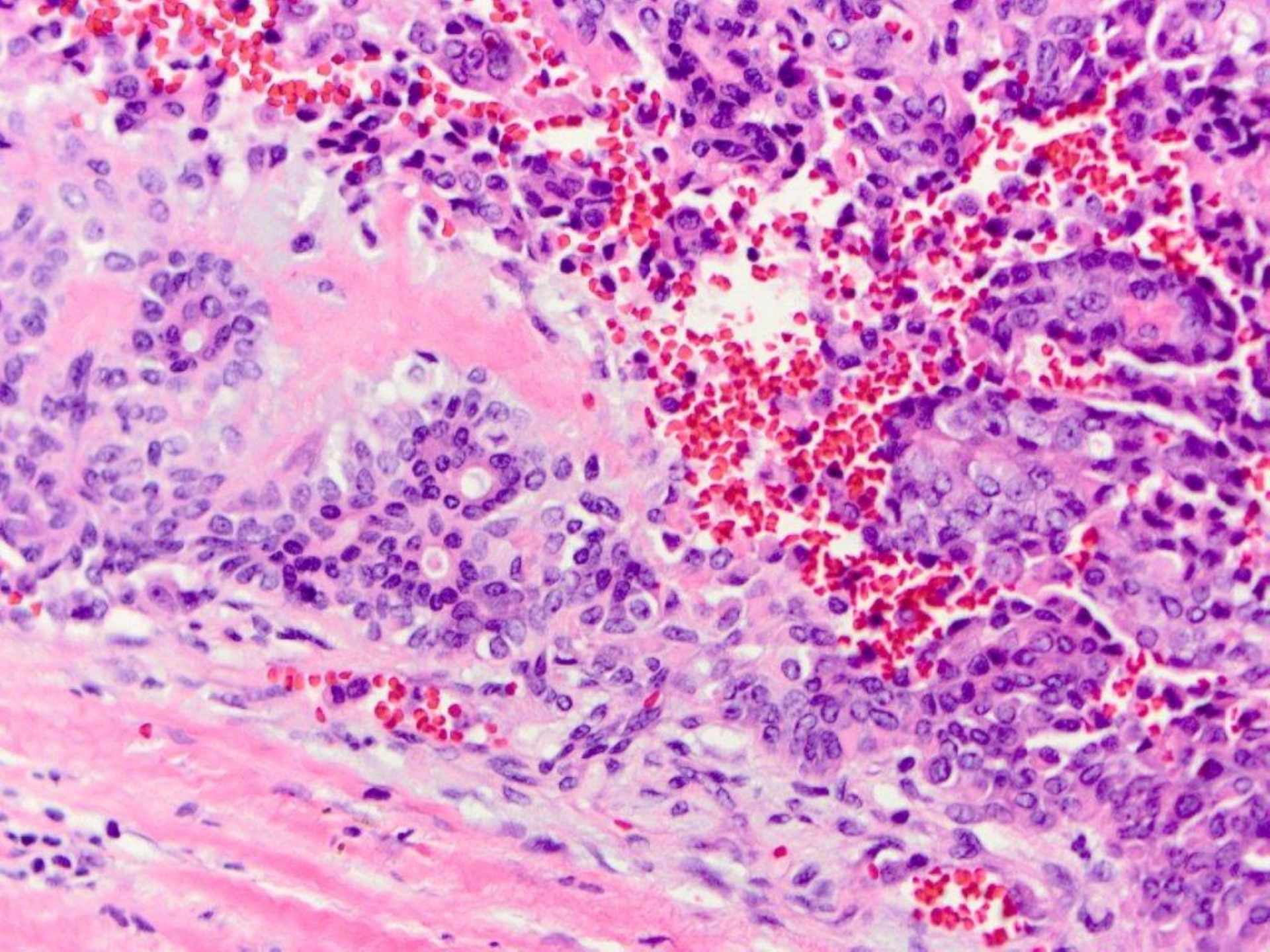


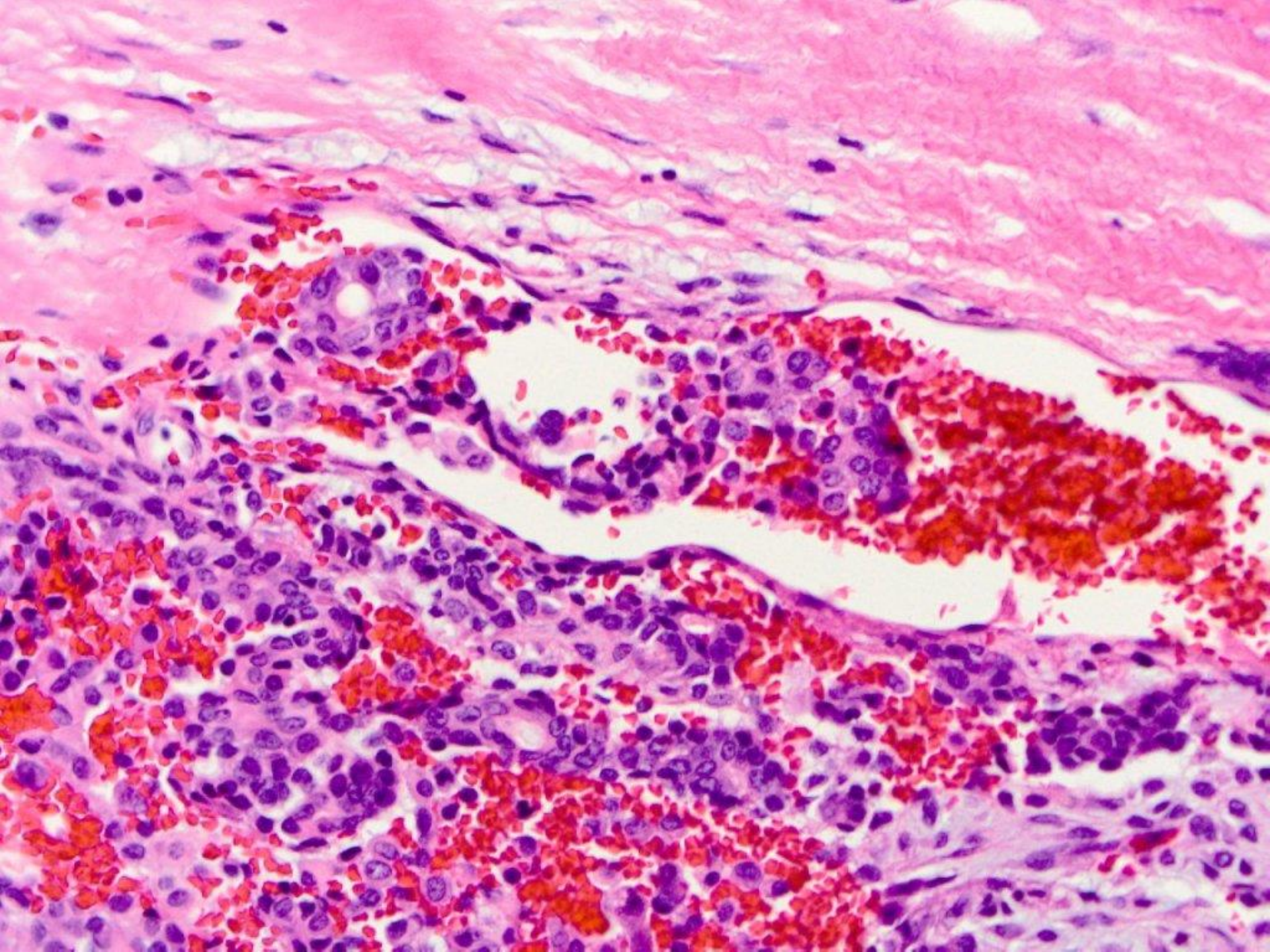


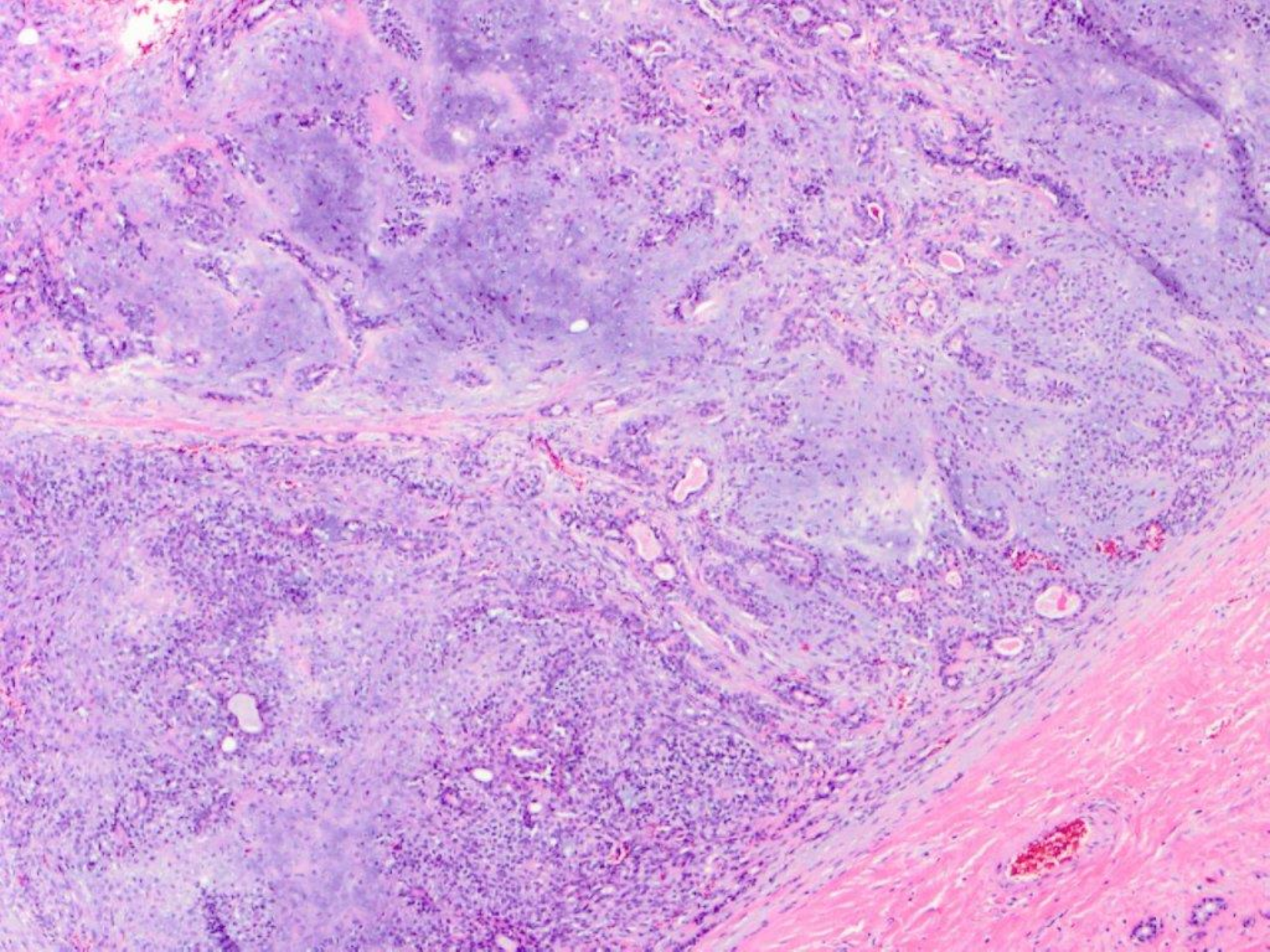


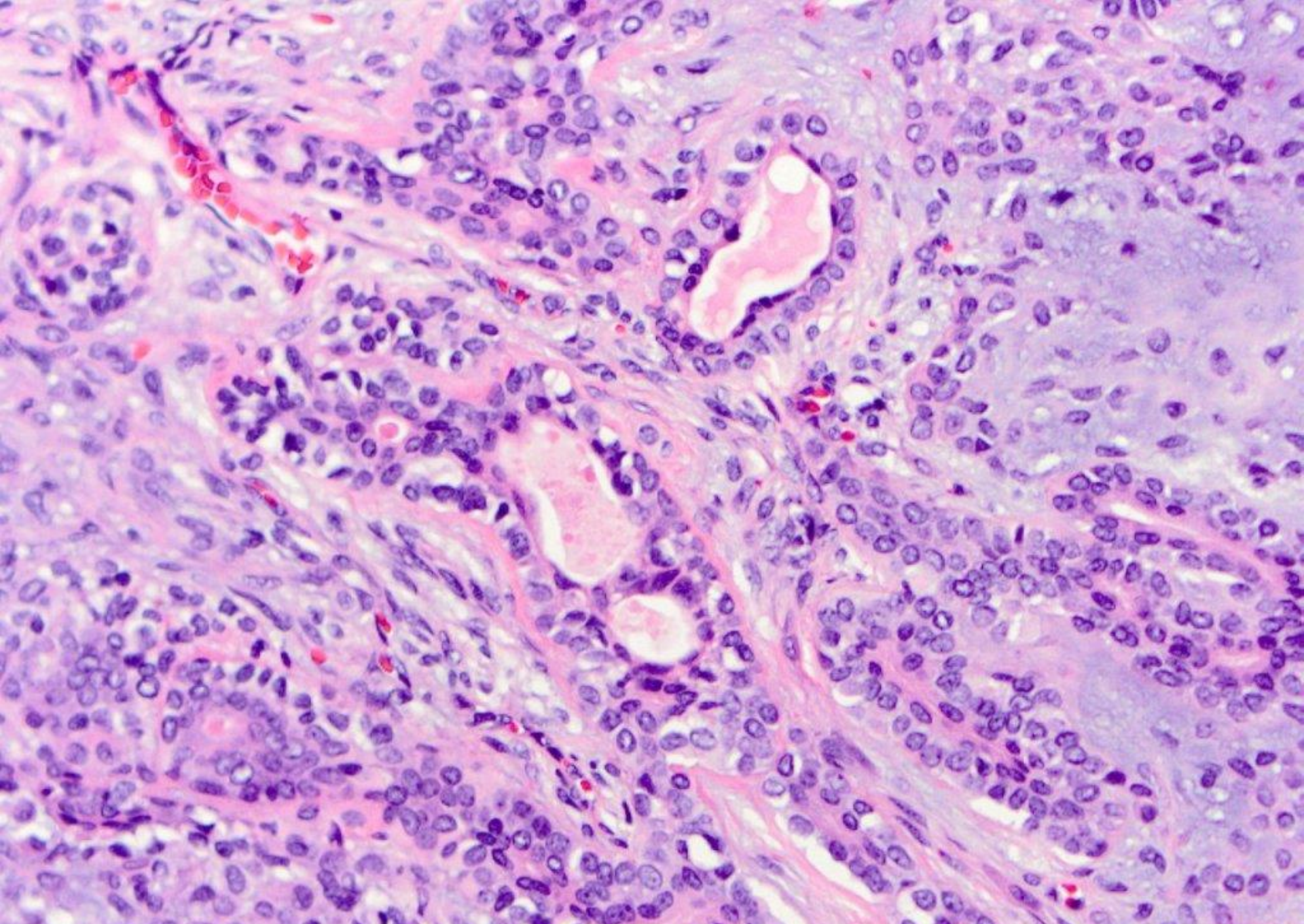












benign mixed tumor (pleomorphic adenoma)